
Welcome Message

Welcome to Kyoto for ASGO the 2nd International Workshop

Hello everybody!

Since The Asian Society of Gynecologic Oncology (ASGO) was established in 2009, two ASGO Meetings and one Workshop have been held in Tokyo and Seoul. Especially, as you remember well, The 2nd ASGO Biennial Meeting 2011 in Seoul was very much successful. Such chances of face to face discussion have greatly stimulated further advancement of our mutual understanding and of new development about treatment and care for gynecological cancer patients in Asian countries. In this meaning, ASGO has become more and more important.

Now we are going to hold The 2nd International Workshop on Gynecologic Oncology in Kyoto Tokyu Hotel, on September 28th, 2012. In this workshop, we will have (1) educational lectures on the recent trends on gynecologic oncology, (2) symposia on the two malignancies with poor prognosis, cervical adenocarcinoma and uterine sarcomas, being composed of lectures from different aspects such as pathology, imaging, and clinical oncology, (3) luncheon session on the recent movement of HPV vaccination in Asia, (4) expert lectures using video on gynecological cancer surgery including laparoscopic and robotic ones, (5) evening session on chemotherapy and surgery for cervical cancer.

We believe, you can fully enjoy the programs of this ASGO workshop. In addition, please attend The 35th Annual Meeting of Japan Society on Obstetrical and Gynecological Surgery in September 29-30. Alternatively, you can enjoy the sight-seeing of beautiful Kyoto in autumn. Anyway, we strongly recommend you to come back and appear in Get-together Party at the same hotel on September 29th evening.

Please join us and be involved in enthusiastic discussions for gynecologic oncology and in various pleasures in Kyoto. We sincerely look forward to seeing you soon.

Best regards,



Toshiharu Kamura, MD, PhD
President of ASGO



Ikuo Konishi, MD, PhD
Congress President of
ASGO the 2nd International Workshop

Scientific Meeting Program

September 27 (Thu) ASGO Council Meeting 17:00-18:30 Place: Kurama, 1F, Kyoto Tokyu Hotel
Welcome Reception 19:00-21:00 Place: Miyabi, 2F, Kyoto Tokyu Hotel

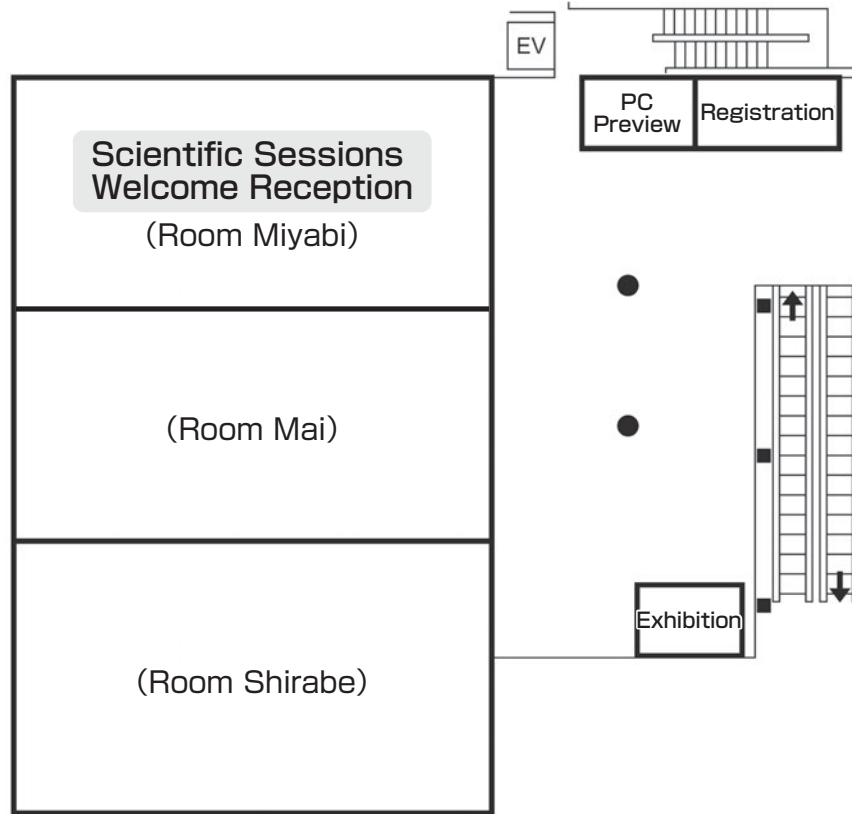
September 28 (Fri) Scientific Meeting

Room Miyabi	
9:00	8:45-9:00 Opening Remarks
9:00	9:00-10:00 Topics 1 "Recent Trends in Gynecologic Oncology" Chairpersons: Seung-Cheol Kim (Korea) Noriyuki Inaba (Japan) Speakers: Zeyi Cao (China) Mohamad F. Aziz (Indonesia) K. Uma Devi (India)
10:00	10:00-10:30 Coffee Break
11:00	10:30-12:30 Topics 2 "Round Table Discussion for Malignancy with Poor Prognosis" (1) Cervical Adenocarcinoma Chairpersons: Hextan YS Ngan (Hong Kong) Tadashi Kimura (Japan) Speakers: Yoshiki Mikami (Japan) Tanri Shiozawa (Japan) Young-Tak Kim (Korea)
12:00	12:00-12:30 (2) Uterine Sarcomas Chairpersons: Kung-Liahng Wang (Taiwan) Hiroshi Kobayashi (Japan) Speakers: Steven G. Silverberg (USA) Ting-Chang Chang (Taiwan) Tadao Takano (Japan)
13:00	12:40-13:40 Luncheon Seminar "Prevention of Cervical Cancer in Asia" Chairpersons: Kazunori Ochiai (Japan) Jo Kitawaki (Japan) Speakers: Sarikapan Wilailak (Thailand) Ryo Konno (Japan) Sponsored by GlaxoSmithKline K. K. & Japan Vaccine Co., Ltd.
14:00	14:00-15:00 Topics 3 "Translational Research for Ovarian Cancer" Chairpersons: Hee Sug Ryu (Korea) Hidetaka Katabuchi (Japan) Byoung-Gie Kim (Korea) Speakers: Liang Kee Goh (Singapore) David W Chan (Hong Kong) Chunling Chen (China) Noriomi Matsumura (Japan)
15:00	15:00-15:30 Coffee Break
16:00	15:30-16:30 Topics 4 "Updating Gynecologic Cancer Surgery: Film Session" Chairpersons: Efen Domingo (Philippines) Hideharu Kanzaki (Japan) Speakers: Tadayoshi Nagano (Japan) Sang-Yoon Park (Korea) Kung-Liahng Wang (Taiwan)
17:00	16:30-17:30 Topics 5 "Minimally Invasive Surgery for Gynecologic Cancer: Film Session" Chairpersons: Duk-Soo Bae (Korea) Daisuke Aoki (Japan) Speakers: John Fletcher Boggess (USA) Yoon Soon Lee (Korea) Young Tae Kim (Korea)
18:00	17:30-18:30 Evening Seminar "Neoadjuvant Chemotherapy (NAC) for Cervical Cancer" Chairpersons: Toru Sugiyama (Japan) Jyunzo Kigawa (Japan) Speakers: Nobuhiro Takeshima (Japan) Masaki Mandai (Japan) Sponsored by Yakult Honsha Co., Ltd.
19:00	18:30-18:45 Closing Remarks

September 29 (Sat) Get Together Party 18:00-20:00 Place: Gion+Kurama, 1F, Kyoto Tokyu Hotel

Floor Plan

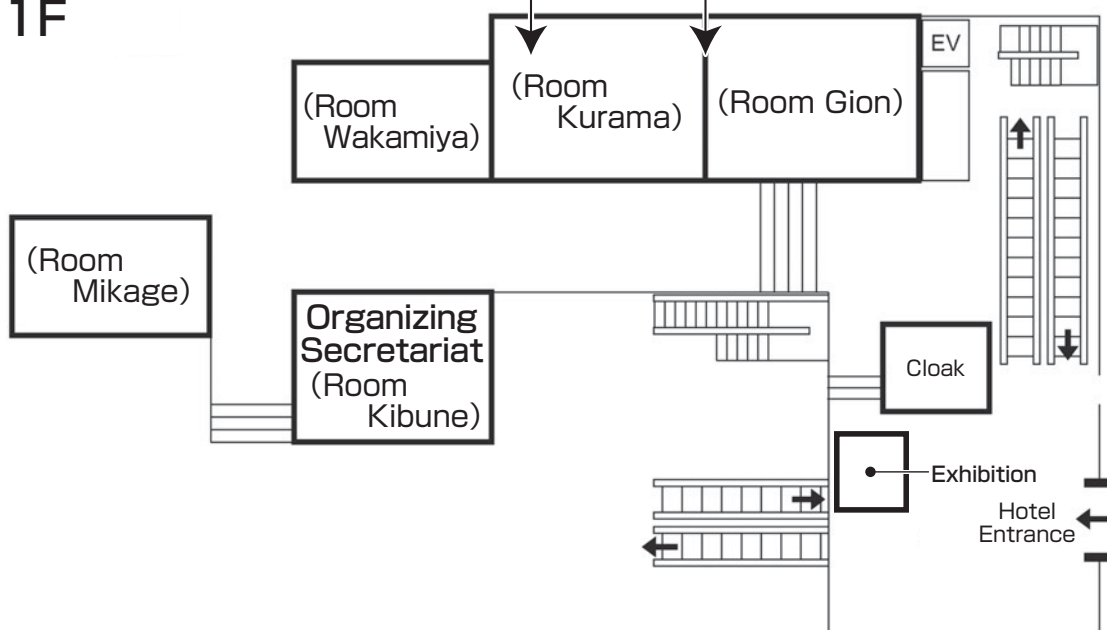
2F



17:00~18:30,
September 27(Thu)
ASGO Council Meeting

18:00~20:00, September 29(Sat)
Get Together Party
(Room Gion+Kurama)

1F



Program

Abstracts

Program

Opening Remarks

8:45~9:00

Toshiharu Kamura (President of ASGO, Japan)
Soon Beom Kang (Past President of ASGO, Korea)
Shingo Fujii (President of IGCS, Japan)

Topics1 Recent Trends in Gynecologic Oncology

9:00~10:00

Chairpersons: Seung-Cheol Kim (Korea)
Noriyuki Inaba (Japan)

- 1. The Management of Locally Advanced Cervical Cancer in Young Women**
Zeyi Cao (Beijing Royal Integrative Medicine, China)
- 2. Neoadjuvant Chemotherapy in Advanced Ovarian Cancer**
Mohamad Farid Aziz (Division of Oncology, Department of Obstetrics and Gynecology,
University of Indonesia, Indonesia)
- 3. Current Management of Gestational Trophoblastic Disease**
K. Uma Devi (Department of Gynaecologic Oncology, Kidwai Memorial Institute of Oncology,
Bangalore, Karnataka, India)

Topics2 Round Table Discussion for Malignancy with Poor Prognosis 10:30~12:30

(1) Cervical Adenocarcinoma

Chairpersons: Hextan YS Ngan (Hong Kong)
Tadashi Kimura (Japan)

- 1. Cervical Adenocarcinoma of Gastric-type: A New Entity**
Yoshiki Mikami (Department of Diagnostic Pathology, Kyoto University Hospital, Kyoto,
Japan)
- 2. Preoperative Differential Diagnosis of Minimal Deviation Adenocarcinoma (MDA) and Lobular Endocervical Glandular Hyperplasia (LEGH) of the Uterine Cervix by Clininopathology and Magnetic Resonance Imaging (MRI) Findings**
Tanri Shiozawa (Department of Obstetrics and Gynecology, Shinshu University School of
Medicine, Matsumoto, Japan)
- 3. Current Management of Cervical Adenocarcinoma**
Young-Tak Kim (Department of Obstetrics and Gynecology, College of Medicine, University of
Ulsan, Asan Medical Center, Seoul, Korea)

(2) Uterine Sarcomas

Chairpersons: Kung-Liahng Wang (Taiwan)
Hiroshi Kobayashi (Japan)

1. Pathology of Sarcomas of the Uterus

Steven G. Silverberg (University of Maryland, Baltimore, USA)

2. Does MRI help in Diagnosing Uterine Sarcomas?

Ting-Chang Chang (Department of Obstetrics and Gynecology, Chang Gung Memorial Hospital Linkou Medical Center, Taiwan)

3. Recent Advances in Management of Uterine Sarcomas

Tadao Takano (Clinical Research, Innovation, and Education Center, Tohoku University Hospital, Japan)

Luncheon Seminar Prevention of Cervical Cancer in Asia

12:40~13:40

Sponsored by GlaxoSmithKline K. K. & Japan Vaccine Co., Ltd.

Chairpersons: Kazunori Ochiai (Japan)
Jo Kitawaki (Japan)

1. HPV Vaccination in Asia: Globalization of Combat against Cervical Cancer

Sarikapan Wilailak (Department of Obstetrics and Gynecology, Faculty of Medicine, Ramathibodi Hospital, Mahidol University, Bangkok, Thailand)

2. How to Get National Immunization Program for HPV Vaccination: Sharing Experience — The Japanese Expert Board for the Eradication of Cervical Cancer

Ryo Konno (Department of Obstetrics and Gynecology, Jichi Medical University Saitama Medical Center, Saitama, Japan)

Topics3 Translational Research for Ovarian Cancer

14:00~15:00

Chairpersons: Hee Sug Ryu (Korea)
Hidetaka Katabuchi (Japan)
Byoung-Gie Kim (Korea)

1. Histotype-specific Genomics Alterations in Ovarian Cancer

Liang Kee Goh (Cancer & Stem Cell Biology, Duke-NUS Graduate Medical School, Singapore)

2. The Prognostic and Therapeutic Potential of AMP-activated Protein Kinase in Ovarian Cancer

David W Chan (Department of Obstetrics and Gynecology, LKS Faculty of Medicine, The University of Hong Kong, Hong Kong SAR, P.R.China)

3. The Role of Aberrant MiR-196a Expression In HPV Positive Cervical Cancer

Chunling Chen (Department of Obstetrics and Gynecology, Beijing Royal Intergrative Medicine Hospital, China)

4. Biology of Ovarian Clear Cell Carcinoma: Microarray Analysis and Bioinformatics

Noriomi Matsumura (Department of Gynecology and Obstetrics, Kyoto University Graduate School of Medicine, Kyoto, Japan)

Topics4 Updating Gynecologic Cancer Surgery: Film Session

15:30~16:30

Chairpersons: Efren Domingo (Philippines)
Hideharu Kanzaki (Japan)

1. Abdominal Radical Trachelectomy

Tadayoshi Nagano (The Tazuke Kofukai, Medical Research Institute, Kitano Hospital, Osaka, Japan)

2. Cytoreductive Surgery for Advanced Ovarian Cancer

Sang-Yoon Park (National Cancer Center, Korea)

3. Laparoscopic Surgery for Gynecological Cancer

Kung-Liahng Wang (Mackay Memorial Hospital, Taipei, Taiwan)

Topics5 Minimally Invasive Surgery for Gynecologic Cancer: Film Session

16:30~17:30

Chairpersons: Duk-Soo Bae (Korea)
Daisuke Aoki (Japan)

1. Robotic Surgery for High Risk Endometrial Cancer

John Fletcher Boggess (Department of Obstetrics and Gynecology, Division of Gynecologic Oncology, University of North Carolina, Chapel Hill, NC, USA)

2. Robotic Radical Hysterectomy for Cervical Cancer

Yoon Soon Lee (Gynecologic Cancer Center, Kyungpook National University Medical Center, Daegu, Korea)

3. Fertility-sparing Robotic assisted Radical Trachelectomy in Early-Stage Cervical Cancer

Young Tae Kim (Division of Gynecologic Oncology, Department of Obstetrics and Gynecology, Institute of Women's Life Medical Science, Yonsei University College of Medicine, Seoul, Korea)

Evening Seminar Neoadjuvant Chemotherapy (NAC) for Cervical Cancer

17:30~18:30

Sponsored by Yakult Honsha Co., Ltd.

Chairpersons: Toru Sugiyama (Japan)
Jyunzo Kigawa (Japan)

1. Neoadjuvant Chemotherapy followed by Radical Hysterectomy plus Postoperative Chemotherapy but No Radiotherapy for Stage IB2-IIB Cervical Cancer

Nobuhiro Takeshima (Department of Gynecology, Cancer Institute Hospital, Tokyo, Japan)

2. Radical Hysterectomy for Locally Advanced Cervical Cancer: Essential Techniques

Masaki Mandai (Department of Gynecology and Obstetrics, Kyoto University Graduate School of Medicine, Kyoto, Japan)

Closing Remarks

18:30~18:45

Joo-Hyun Nam (President-Elect of ASGO)
Ikuro Konishi (Congress President of The 3rd Biennial Meeting of ASGO)

Program

Abstracts

The Management of Locally Advanced Cervical Cancer in Young Women

Zeyi Cao

Beijing Royal Integrative Medicine, China

Cervical cancer is the most common gynecological malignancy. Locally advanced cervical cancer is a group of high-risk cervical cancer with poor prognostic factors. And in a narrow sense it refers to the early cervical cancer with local tumor volume > 4cm (IB2 by FIGO Stage). The young cervical cancer patients usually refer to the women younger than 35 years old. The requirements for retention of endocrine function and vaginal function in these women is urge. So the special treatment for these women should be investigated.

Surgery is the primary treatment for the young locally advanced cervical cancer women. The ovarian transposition surgery can reduce radiation damage to ovary and vaginal replace by peritoneum will help restore sexual function of patients accepting radical hysterectomy.

The current studies support the effectiveness of neoadjuvant chemotherapy in the treatment of locally advanced cervical cancer. Platinum-based combination plan is commonly used, such as TP program. The clinic effect of neoadjuvant intraarterial chemotherapy is superior to intravenous drip. By shrinking the size of the tumor, neoadjuvant chemotherapy can provide operation chance for the locally advanced cervical cancer women whose tumor is so large that removing it is so difficult.

Radiotherapy has a good effect for locally advanced women. But it is easy to damage ovaries and vagina. As a result, the radiotherapy is not the preferred treatment measures.

In conclusion, the main treatment for young women with locally advanced cervical cancer should be surgical excision as chief component of combined therapy. In order to improve patient's quality of life we should pay special attention to the retention of physiological functions.

Curriculum Vitae

Professor, Obstetrics and Gynaecology

President, Chinese Society of Gynaecological Oncology

Honorary President, Chinese Society of Obstetrics and Gynaecology

Chief Editor, International Journal of Gynecological Cancer (Chinese edition)

Director, Beijing Royal Hospital

Dr. Cao graduated from University of Basel with the Swiss Medical Doctor degree in 1982. He Specializes in the treatment and therapy of Cervica Cance, especially surgical treatment and is the only surgeon performing pelvic exenteratio in the mainland of China at present. The main research orientation is the pathogenesis of cervical cancer. He is the Editor of "Chinese Obstetrics and Gynaecology"; "China Gynaecologic Oncology"; and many other Chinese medical books. "Chinese Obstetrics and Gynaecology" is the most authoritative book in Obstetrics and Gynaecology in China.

Neoadjuvant Chemotherapy in Advanced Ovarian Cancer

Mohamad Farid Aziz

Division of Oncology, Department of Obstetrics and Gynecology, University of Indonesia, Indonesia

Standard therapy in ovarian cancer is surgery with or without chemotherapy. Overall five years survival rate is very low and the increment is also small, less than twice during four decades. The overall 5 years survival rate in the period 1958-62 was 26.8% increased to 49.7% in the period 1999-2001. The increments of 5 years survival rate for stage III and IV were greater. The survival for stage III and IV in the period 1958-62 were 6.9% and 2.6% respectively and in the period 1999-2001 were 40.2% (36.5-46.7%) and 18.6% respectively (1). The improvement in survival was prominent since cisplatin era. One of the important determinant for survival is residual tumors (1). That's way the purpose of the bulking surgery is to obtain no residual tumor. Recently there is an effort to obtain it by administrating chemotherapy prior surgery or neoadjuvant chemotherapy (NAC). From several publications regarding NAC, the survival and disease free survival are not different significantly with primary debulking (2, 3, 4) but the advantages are less morbidity, less bleeding, more resectable and less hospitalization (5). Progressive free survival (PFS) after NAC is related with suboptimal cytoreduction and initial ascites (6). Predictive factors for irressectability in advanced ovarian cancer are age over 60 years (7), ascites and Ca 125 (7, 8, 9), the presence of palpable tumor on physical examination, tumor in Douglas cul de sac on vaginal exploration, pulmonary and liver metastases or upper abdominal metastases (8, 10). And the most reliable tool to identify patients with stage III/IV ovarian cancer who qualify for primary cytoreduction is diagnostic laparoscopy (11). PET/CT is superior to that of CT alone in initial staging, but the sensitivity of both in the detection of carcinomatous is limited (12). The optimal courses of NAC is 3 courses, more than 3 survival will decrease (13).

Conclusion: NAC prior cytoreductive surgery is not superior than primary cytoreductive surgery in advanced stage III and IV ovarian cancer, but less morbidity and less hospitalization.

References:

1. Heintz APM, Odicino F, Maisonneuve P, Quinn MA, Benedet JL, Creasman WT, Ngan HYS, Pecorelli S, and Beller U. FIGO 26th Annual Report on the Results of Treatment in Gynecological Cancer. Carcinoma of the Ovary. *Int J Gynaecol Obstet.* 2006 Nov;95 Suppl 1:S161-92.
2. Kang S, Kim T J, Seo SS, Kim BG, Bae DK Duk-Soo Bae, Park SY. Interaction between preoperative CA-125 level and survival benefit of neoadjuvant chemotherapy in advanced epithelial ovarian cancer. *Gynecologic Oncology* 120 (2011) 18-22
3. Ignace Vergote, M.D., Ph.D., Claes G. Tropé, M.D., Ph.D., Frédéric Amant, M.D., Ph.D., et al. Neoadjuvant Chemotherapy or Primary Surgery in Stage IIIC or IV Ovarian Cancer. *N Engl J Med* 2010;363:943-53.
4. Loizzi V, Cormio G, Restay L, Rossi C A, Di Gilio A R, Cuccovillo A, Selvaggi L. Neoadjuvant chemotherapy in advanced ovarian cancer: a case-control study. *Int J Gynecol Cancer* 2005, 15, 217-223.
5. Milam MR, Xia Tao, X, Coleman RL, Harrell R, Bassett, dos Reis R, and Ramirez PT. Neoadjuvant Chemotherapy Is Associated With Prolonged Primary Treatment Intervals in Patients With Advanced Epithelial Ovarian Cancer. *Int J Gynecol Cancer* 2011;21: 66-71
6. Kang S, Kim TJ, seo SE, Kim BG, Bae DK, Park SY. Interaction between preoperative CA-125 level and survival benefit of neoadjuvant chemotherapy in advanced epithelial ovarian cancer. *Gynecologic*

● Topics 1-2

Oncology 120 (2011) 18-22

7. Brockbank EC, Ind TEJ, Barton DPJ, Shepherd JH, Gore ME, A'Hern R, Bridges JE. Preoperative predictors of suboptimal primary surgical cytoreduction in women with clinical evidence of advanced primary epithelial ovarian cancer. *Int J Gynecol Cancer* 2004, 14, 42-50
8. Sa'id HM, Rinco'n DG, Ruiz GC, Ponce JLA, Lo'pez-Graniel CM. Predictive factors for irresectability in advanced ovarian cancer. *Int J Gynecol Cancer* 2004, 14, 423-430
9. Vasudev NS, I, Trigonis I, Cairns DA, Hall GD, Jackson DV, Broadhead T, Buxton J, Hutson R, Lane G, Nugent D, and Perren TJ. The prognostic and predictive value of CA-125 regression during neoadjuvant chemotherapy for advanced ovarian or primary peritoneal carcinoma. *Arch Gynecol Obstet.* 2011 July ; 284(1): 221-227
10. Le T, Faught W, Hopkins L, Fung Kee Fung M. Primary chemotherapy and adjuvant tumordebulking in the management of advanced-stage epithelial ovarian cancer. *Int J Gynecol Cancer* 2005, 15, 770-775.
11. Brun JL, Roman Rouzier R, Selle F, Houry S, Uzan S and Daraï E. Neoadjuvant chemotherapy or primary surgery for stage III/IV ovarian cancer: contribution of diagnostic laparoscopy. *BMC Cancer* 2009, 9:171.
12. Schwarz JK, Grigsby PW, Dehdashti F, and Dominique Delbeke D. The Role of 18F-FDG PET in Assessing Therapy Response in Cancer of the Cervix and Ovaries. *J Nucl Med* 2009; 50:64S-73S
13. Bristow RE, Chi DS. Platinum-based neoadjuvant chemotherapy and interval surgical cytoreduction for advanced ovarian cancer: A meta-analysis. *Gynecologic Oncology* 103 (2006) 1070-1076

Curriculum Vitae

Institution:

Division of Oncology, Department of Obstetrics and Gynecology
University of Indonesia, Jakarta

1968	Graduated Medical Faculty University of Indonesia
1972-76	Residency/Training in Obstetrics and Gynecology, University of Indonesia
1976-	Staff of Department of Obstetrics and Gynecology, University of Indonesia
1983	Training in Gynecologic Oncology at King George, University of Sydney, Australia
1983	Training in Oncology at Royal Women Hospital, University of Melbourne, Australia
1990-2000	Chairman Division of Oncology Department of Obstetrics and Gynecology, University of Indonesia
2003	PhD, Medical Faculty University of Indonesia
2004	Professor in Gynecologic Oncology
2006-08	Chairman of Medical Research Unit, Medical Faculty University of Indonesia
2009-	Editor Member of Journal of Gynecologic Oncology
2009-	Council Member of Asian Society of Gynecological Oncology
2000-12	President of Indonesian Society of Gynecological Oncology
2012	Immediate Past President Indonesian Society of Gynecological Oncology
2012-	Chairman of the Committee of subspecialist training in Obstetrics and Gynecology, Indonesian Society of Obstetrics and Gynecology

Current Management of Gestational Trophoblastic Disease

K. Uma Devi

Department of Gynaecologic Oncology, Kidwai Memorial Institute of Oncology, Bangalore, Karnataka, India

INTRODUCTION:

Gestational Trophoblastic Disease (GTD) is a spectrum of interrelated diseases including complete mole, partial molar pregnancy, invasive mole, placental site trophoblastic tumour (PSTT) & choriocarcinoma (CCA). Gestational Trophoblastic Neoplasia (GTN) is a spectrum of heterogeneous conditions which arises from the products of conception, presents mysteriously, that have a varying propensities for local invasion and metastases, if not detected & treated early, may threaten the health of young reproductive women. The reported incidence of GTN varies in different region of the world, frequently occur among southeast Asian women.

INVESTIGATIONS:

Most patients who develop gestational trophoblastic neoplasia after hydatidiform mole are detected early by serum beta hcg monitoring, hence detailed investigations are rarely required. Pulmonary metastasis are most common, if the lesions are found on chest radiograph, then brain MRI & body CT are recommended to exclude more widespread disease affecting brain or liver which would substantially change the management. Less often young women do present with Vaginal & cervical metastases. Disease vascularity suggest patients who are at risk of treatment resistance. However, the majority of women with low risk of this disease will be cured by using single agent mono chemotherapy either with methotrexate or dactinomycin by using Modified Bhagshaw's WHO prognostic scoring system or FIGO report data for gestational trophoblastic neoplasia of prognostic scoring and anatomical staging systems.

PROGNOSTIC SCORING:

The combined prognostic score predicts potential for development of resistance to monotherapy with **methotrexate** or **dactinomycin**. A **score of 0-6** suggest **low risk** & **7 or more** indicate **high risk**. Only 30% of patients scoring 5-6 can be cured with low risk therapy. The amount of vascularisation as detected on Doppler ultrasonography could help to provide the necessary additional information. Such disease has almost no chance of being cured with monotherapy and needs multidrug treatment. Therefore the revision of the FIGO scoring system would be helpful for early identification of 70% of women in this group who subsequently develop resistance to methotrexate with folinic acid rescue & who may need more intensive therapy.

TREATMENT:

Majority of the women with FIGO stage I & II disease or women with low risk of this disease are often treated with parental use of single agent methotrexate 1mg/kg/day on day 1, 3, 5, 7, along with folinic acid 0.1mg/kg/day on day 2, 4, 6, & 8 at weekly interval or dactinomycin 10-12 microgram/day on day 1-5, at ten days interval. These low risk women usually respond to these regimen, very rarely require an alternative or combination therapy.

● Topics 1-3

Most patients with high risk gestational trophoblastic disease present with many metastases months or years after the causative pregnancy of any type. Symptoms & signs vary with disease location. The optimal management of these high risk women depends on prompt diagnosis, proper treatment and reference to centre with expertise in the management of such disease.

EMA-CO as a multi-drug chemotherapy remain the preferred treatment of high risk gestational trophoblastic neoplasia [Etoposide 100mg/m² on day 1 & 2, dactinomycin on day 1 & 2, Methotrexate 100 mg/m² IV bolus, 200mg/m² IV infusion on day1, dactinomycin 10-12 microgm/kg on day 1&2 & cyclophosphamide 600mg/m² & vincristine 1-1.5mg/m² on day 8] and has a successful outcome with minimal toxicity and a cure rate 80-85% reported worldwide.

TREATMENT FOR RELAPSE/REFRACTORY DISEASE:

Those women who progress during or after primary chemotherapy still can be salvaged with EP-alternating every week with EMA chemotherapy as **EP-EMA** regimen [Etoposide 100mg/m² & Cisplatinum 100 mg/m² on day 1, & Etoposide 100mg/m², dactinomycin 0.5mg/m², on day 8 & 9, Methotrexate 100mg/m² IV bolus, along with 200mg/m² IV infusion, along with folinic acid 15mg, every twelfth hourly for 48 hrs on day 9&10]. Survival is more than 80% but toxic effects are substantial. PET scanning with 18 F-fluorodeoxyglucose may help to identify the site of active disease to aid surgical resection and cure.

Patients with relapsed or refractory neoplasia, Pacli-Cisplatin & Paclitaxel-Etoposide [**TP-TE**] every 2 weeks seems to be much better tolerated than EP-EMA regimen. High dose chemotherapy with peripheral stem cell transplantation does not cure many patients with refractory disease.

PLACENTAL SITE TROPHOBLASTIC TUMOUR:

Placental site trophoblastic tumour [PSTT], unlike that of choriocarcinoma, slow growing, metastasize more eventually to involve lymphnodes & produce less hcg, surgery may be prudent in women with localized disease, however in metastatic tumour, optimum therapy is yet to be defined. Surgery may be prudent in early disease, however it is often difficult to diagnose, often diagnosed by the post hysterectomy specimen but rarely women do present with fulminant metastatic disease, it will be challenging task to treat. Despite of adequate chemotherapy patient do relapse & die with progressive disease.

CHORIOCARCINOMA:

When reported by the histopathology, treatment should be initiated according to the prognostic scoring without waiting for the raise or fall of beta serum hCG report. Surveillance of these patients for every month with beta serum hCG, clinical history & examination for twelve months in low risk & twenty four months in high risk is necessary to identify the relapse/refractory patients. Surgery & Radiation therapy has a minimum role in the management of GTT.

Although gestational trophoblastic neoplasia is considered to be more chemosensitive tumour, with more than 98% outcome, a few women die from the disease, mainly because of late presentation, diagnosis & drug resistance. Novel approach with improved efficacy & reduced toxicity need to be identified with the establishment of national registries of gestational trophoblastic centres in Asia.

Key Words : Gestational Trophoblastic Disease, Current Treatment, Outcome.

Curriculum Vitae

DR. UMA K. DEVI, graduated her Bachelor of Medicine & Bachelor of Surgery [M.B.B.S] from Bangalore Medical College, Bangalore University, bonafied with Master degree & Diploma degree [M.D ; D.G.O.] in Obstetrics and Gynaecology from Mysore University in 1986 & 1985.

Served as a Registrar/Senior resident equivalent to Lecturer in the Department of Obstetrics and Gynaecology at Jawaharlal Institute of Postgraduate Medical Education and Research [JIPMER], Pondicherry from 1986-1990 March.

From March 1990 till date working as a faculty in the Dept of Gynaecological Oncology Kidwai Memorial Institute of Oncology, Bangalore, Karnataka State, India.

Awarded with WHO Fellowship through Government of India in 1994-1995 and trained in Gynaecologic Oncology and Palliative care at Royal Hospital for Women, Sydney, Australia, under the noble guidance of Professor Doctor Neville F Hacker and in Uro-Gynaecological Oncology at KKWCH, Singapore.

Awarded with National Merit Scholarship, IGCS travel grant scholarship to participate at the First pre-congress workshop at Rome, Italy in 1999, to Develop the subspeciality in Gynaecological Oncology targeting to developing countries. Trained at various University at Lyon, France, Leuven, EU & Seoul, S. Korea for Gynaec Onco laparoscopic, Robotic surgeries & advanced surgical techniques in Gynaec Onco & Breast cancer surgeries. Awarded with IGCS Travel grant to visit University of Leuven in 2009 & ISSTD travel grants to participate at World congress -2009 at Kochi, India.

Performing all types of Radical Gynaec Onco Surgeries, teaching postgraduate students of obstetrics & Gynaecology & training the postdoctoral fellows of Onco Surgery, Gynaec Oncology, Medical & Radiation Oncology from RGHUMS & other various Universities of India.

Member of several National & International Organizations including AGOI, ASGO, IGCS, ESGO, FIGO, ISO, ISAMPO, FOGSI...Published & presented many papers in national & International journals, contributed chapters in several gynaec onco books & **Editor of Atlas of Gynaec Cancer Surgery.**

Member of Editorial board of JGO, former member of the editorial board in IJGC, IJGO, reviewer in IJC, IJGO & member of several advisory boards including HPV & Vaccine. Invited speaker & faculty in many National & International congress/forum.

Served as a Council member, Vice President, of the Association of Gynaecological Oncologists of India [AGOI]. Former Hon. Secretary General, **currently the President of AGOI, India & Council member of ASGO-Asia** & Former Council member of AOGIN-India chapter.

Field of interest is to **promote, provide, facilitate, create & establish Gynaec Oncology as a subspeciality in India as IIGO & Breast cancer Care Foundation & Research Training Centre of excellence in our country** to improve the pattern of standard care to all our women suffering from gynaec & breast cancer. **To establish Clinical research & Gynaec Onco Wing in all Medical Colleges & University affiliated Institutions.** However, the goal is to make **eradication of cervical cancer from India & provide quality of life to all our women free from Gynaec & Breast cancer** by chemoprevention in Gynaec & Breast cancer through innovative research. **Main aim is to serve the poor cancer women in public sector & teach & train the committed team to establish Gynaecological Oncology as IIGO in all five zones as an Centre of Excellence in Gynaec Oncology in our Country.**

Cervical Adenocarcinoma of Gastric-type: A New Entity

Yoshiki Mikami

Department of Diagnostic Pathology, Kyoto University Hospital, Kyoto, Japan

Minimal deviation adenocarcinoma (MDA) is an extremely well-differentiated form of endocervical adenocarcinoma, which has also been called “adenoma malignum”. Although it is only rarely seen in a practical setting, accounting for 1 to 3% of all endocervical adenocarcinomas, the confusing but rather fascinating name “adenoma malignum” has been preferred by pathologists and gynecologists historically. During the last decade this particular tumor has been a matter of controversy because of its unique gastric immunophenotype and relationship to lobular endocervical glandular hyperplasia (LEGH) in histogenesis. From a practical point of view, critical issues regarding MDA are summarized as follows; (1) How to distinguish MDA and LEGH from each other preoperatively, (2) Management of patients with possible LEGH, and (3) clinicopathologic aspects of mucinous adenocarcinoma with gastric immunophenotype and morphology (“gastric-type adenocarcinoma (GAC)”).

In 1998, Ishii et al demonstrated that MDA shows gastric phenotype as evidence by immunoreactivity for HIK1083, an antibody recognizing pyloric gland mucin of the stomach, and thereafter the HIK1083 immunohistochemistry has been recognized as a diagnostic tool for MDA. In 1999, however, Nucci et al first described LEGH as a worrisome mimic of MDA, which is now considered to represent pyloric gland metaplasia. This unique pseudoneoplastic glandular lesion also shows positive staining with HIK1083 (Mikami et al., 2001), and more importantly accumulated experiences indicate occasional cases of LEGH harbor distinct nuclear anaplasia, which can be associated with invasive adenocarcinoma including MDA (Mikami et al., 2004; Kondo et al., 2005; Nara et al., 2007; Takeuchi et al., 2008; Ohta et al., 2008). In addition, LEGH with significant cytologic atypia (atypical LEGH) shows over-expression of p53 protein and increased Ki-67 labeling index (Mikami et al., 2009), and numerical chromosomal abnormalities, some of which are shared by MDA (Kawauchi et al., 2008). Interestingly enough, high risk HPV DNA is only rarely detected in cases of MDA with a rate of 20% (2/19) in the English literature (Fukushima et al., 1990; Ferguson et al., 1998; Toki et al., 1999), and Xu et al. showed absence of HPV in LEGH in 2005. It has been widely accepted that endocervical adenocarcinoma as well as squamous cell carcinoma is high risk HPV-driven neoplasm with prevalence up to 85% in the English literature (International Collaboration of Epidemiological Studies of Cervical Cancer, 2007). These facts suggest that MDA arise in association with atypical LEGH via high risk HPV-independent pathway.

In 2007, Kojima and Mikami et al have demonstrated that mucinous adenocarcinoma showing gastric immunophenotype shows distinct morphology and proposed a concept of gastric-type adenocarcinoma (GAS) of the cervix. Importantly, the GAS shows aggressive behavior, resulting in unfavorable clinical outcome, compared with usual-type endocervical adenocarcinoma. In addition, absence of HPV DNA (Park et al., 2008; Houghton et al., 2010; Kusanagi et al., 2010) in this particular type of tumor indicates that GAS arise via HPV-unrelated pathway. Conceptually, MDA can be included in the morphologic spectrum of GAS as its well-differentiated form. Approximately 20-30% of “endocervical-type” mucinous adenocarcinoma of the uterine cervix on the current WHO (2003) scheme fulfills the morphologic criteria of GAS established by Kojima et al., and commonly shows gastric immunophenotype, indicating that in reality “endocervical” mucinous adenocarcinoma is a heterogeneous group of neoplasms, and does not necessarily shows morphologic similarity to endocervical glands. The novel criteria for GAS have been shown to be valid with

good interobserver reproducibility (Kawakami et al., 2010). It should be kept in mind that GAS can be a pitfall of HPV DNA test and vaccination, which are currently believed to contribute to decreasing the morbidity and mortality of cervical cancer.

The cause of aggressive nature of GAS remains to be undetermined, although delay of establishing the diagnosis, advanced stage at the time of diagnosis, resistance to chemoradiation therapy, or a combination of any of these, might be possible explanation, although the recent MSKCC data has shown worse outcome of patients even in stage Ib cases, indicating intrinsic aggressive nature of this particular tumor (USCAP 2012). In conclusion, special considerations might be required for GAS in terms of carcinogenesis, prevention, early detection, and treatment strategy.

Curriculum Vitae

Education

1990 M.D. Hirosaki University, Faculty of Medicine, Hirosaki, Japan

Postgraduate Training

1990-1992 Residency at the Department of Pathology, Tohoku University Hospital

1992-1996 Senior residency at the Department of Pathology, Kawasaki University Hospital, Kurashiki, Japan

Academic Appointment

1996-2001 Assistant professor at the Department of Pathology, Kawasaki Medical School, Kurashiki, Japan

1997-1998 Visiting fellowship, Department of Pathology, New York University Medical Center, NY, NY, USA

2001-2002 Assistant Professor at the Division of Histopathology
Department of Pathology, Tohoku University Graduate School of Medical Science, Sendai, Japan

2002-2005 Assistant Professor at the Department of Diagnostic Pathology, Kyoto University Graduate School of Medical Science

2007-present Associate Professor at the Department of Diagnostic Pathology, Kyoto University Graduate School of Medical Science

Hospital Appointment

1996-2002 Attending Pathologist at the Department of Pathology, Kawasaki Medical School Hospital, Kurashiki, Japan

2002-2005 Attending pathologist at the Department of Pathology, Tohoku University Hospital, Sendai, Japan

2005-Present Vice chairman, Department of Diagnostic Pathology, Kyoto University Hospital

Preoperative Differential Diagnosis of Minimal Deviation Adenocarcinoma (MDA) and Lobular Endocervical Glandular Hyperplasia (LEGH) of the Uterine Cervix by Clininopathology and Magnetic Resonance Imaging (MRI) Findings

Tanri Shiozawa

Department of Obstetrics and Gynecology, Shinshu University School of Medicine, Matsumoto, Japan

Minimal deviation adenocarcinoma (MDA) of the cervix is an extremely well differentiated mucinous adenocarcinoma. Lobular endocervical glandular hyperplasia (LEGH) is a benign lesion characterized by lobular proliferation of small glands. Although LEGH is similar to MDA in terms of pathological findings and clinical symptoms, precise preoperative diagnosis is important for the proper treatment.

To address this issue, we performed a retrospective, multicenter study for the preoperative diagnosis and treatment of MDA and related disorders. In this study, a total of 112 patients who underwent conization or a hysterectomy for suspected MDA were enrolled from 24 hospitals. The pathological diagnosis in each case was determined by a central pathological review (CPR) board. The diagnostic significance of clinicopathological findings including results of magnetic resonance imaging (MRI), Pap smears, and testing for gastric mucin was analyzed.

The result indicated that the CPR identified 37 cases of Nabothian cyst or tunnel cluster, 54 cases of LEGH, 6 cases of MDA, 11 cases of adenocarcinoma, and 4 cases of benign disease. On MRI, LEGH appeared as a characteristic multicystic lesion with an inner solid component, whereas MDA showed a predominantly solid pattern. A Pap smear or gastric mucin alone had limited diagnostic power. However, a combination of these findings was useful, i.e., a cystic structure with inner solid components on MRI associated with mild glandular atypia and gastric mucin strongly suggested LEGH. A solid structure with atypical glandular cells was indicative of MDA or adenocarcinoma.

These data showed that the combination of MRI, Pap smears, and gastric mucin will improve the accuracy of the preoperative diagnosis of MDA and LEGH.

Curriculum Vitae

1986	M.D. Shinshu University School of Medicine. Department of Obstetrics and Gynecology
1990	Ph.D. Graduate School of Medicine, Shinshu University, Department of Obstetrics and Gynecology
1991-93	Post doctoral fellow, University of Washington, Department of Pathobiology The Biomembrane Institute, Seattle USA. (Director: Sen-ichiro Hakomori)
2001	Lecturer, Department of Obstetrics and Gynecology, Shinshu University
2005	Associate Professor, Department of Obstetrics and Gynecology, Shinshu University
2008~	Professor and Chairman, Department of Obstetrics and Gynecology, Shinshu University

Current Management of Cervical Adenocarcinoma

Young-Tak Kim

Department of Obstetrics and Gynecology, College of Medicine, University of Ulsan, Asan Medical Center, Seoul, Korea

The incidence of cervical cancer declines along with popular Pap smear world-widely, but the number of patients with cervical adenocarcinoma (AC) remains unchanged that results into their increased percentage. In many western countries, AC currently accounts for up to 25% of all cases of cervical cancer. This may again be due to the limitations of detecting AC and ASC at screening or it may be that the incidence of AC is truly on the rise. Outcome of AC in comparison with that of SCC was similar in some reports and worse in others. Although some studies fail to show any difference in the prognosis of AC versus SCC, the majority reports AC to have a worse prognosis because it is more likely to progress rapidly and often escapes detection. recently A recent report of a population-based retrospective study on 24,000 patients with cervical carcinoma by Galic et al., showed that the multi-variable odds ratio for death was 1.39 (95% CI, 1.23-1.56) for women with AC compared to those with SCC. We should discuss whether it is now necessary to change the treatment paradigm for the glandular carcinoma of cervix.

Prevention

Although sufficiently high coverage can be achieved, several studies have demonstrated that Pap smears are less beneficial in preventing AC compared with SCC. In one study, patients with AC had significantly higher false-negative results on their most recent Pap smear than patients with SCC ($p < 0.0001$). The time between the most recent Pap smear and the diagnosis of cervical cancer was significantly shorter for patients with AC ($p = 0.01$). Studies that have aimed to determine whether the Pap smear or LBC will be more effective in the detection of glandular abnormalities have reported conflicting results. However, some evidence suggests that LBC has a higher positive predictive power for AC versus standard cytology. Since persistent HPV infection is accepted as the necessary cause of cervical cancer, HPV testing has the potential to be an additional screening tool. There are no specific studies assessing the effect of HPV testing on the detection rates of AIS. However, since AC and SCC are caused by the same HPV types, and in the absence of studies that take into account the potential biologic and clinical differences in HPV types more commonly associated with AC, we can assume that the potential of HPV testing will be comparable for SCC and AC. New screening algorithms have been proposed that employ HPV DNA testing as a primary screening test and use cytology to triage HPV-positive women. The FDA has recently approved a DNA test specific for HPV-16 and HPV-18 that can be used as an adjunct in women who have had a positive HC2 test but a negative Pap smear. However, it is important to also determine an appropriate clinical approach for women who are HPV-16 and -18 negative, have a negative Pap smear, but are positive for one or more of the other oncogenic HPV types. PCR tests that type HPV-positive women may become an important consideration if HPV testing is introduced as a primary screening method, both to identify type-specific persistence on retesting and to monitor the long-term effect of vaccination.

Treatment

Currently, cervical cancer patients with AC histology receive the same front-line treatment as those with SCC histology. However, the prognosis of patients with AC treated either with radical hysterectomy or with

● Topics 2-1-3

definitive radiotherapy is yet to be determined, mainly because of the lack of prospective studies focusing on the prognostic differences between AC and SCC. In patients with locally advanced cervical cancer treated with definitive radiotherapy, adenocarcinoma shows lower response rate to the therapy, and higher recurrence rate than SCC histology. In early stage cervical cancer patients treated with radical surgery, some previous retrospective studies showed that patients with AC have a poorer prognosis than those with SCC, whereas others found no survival differences between the two subtypes. As most of these past studies were conducted before concurrent chemoradiotherapy (CCRT) took a role in the treatment of cervical cancer, the prognostic significance of AC in early stage cervical cancer patients treated with radical hysterectomy plus postoperative CCRT seems yet conclusive. Mabuchi et al. recently reported a retrospective study on 520 patients with FIGO stage IA2-IIb cervical cancer who were treated with radical hysterectomy with or without adjuvant radiotherapy. AC histology was associated with significantly decreased disease-specific survival (DSS) compared with SCC histology in the intermediate- and high-risk groups (hazard ratio: 3.06 and 2.88, respectively, both $P < 0.05$) while there was no survival difference in the low-risk group ($P = 0.1$). Among patients who received any types of adjuvant radiotherapy, DSS of AC histology patients were significantly poorer than SCC histology. Multivariate analysis demonstrated AC histology to be an independent predictor of decreased DSS in both CCRT and RT groups. Moreover, pelvic nodal metastasis significantly predicted the poor survival of patients with AC histology who received CCRT in multivariate analysis.

In conclusion, AC differs from SCC in terms of epidemiology, etiology and prognosis. Cervical adenocarcinoma is an independent prognostic indicator of poor survival in early stage cervical cancer patients with risk factors, regardless of the type of adjuvant radiotherapy after radical hysterectomy. Novel treatment strategies that are specifically tailored to early stage cervical adenocarcinoma are needed.

Reference

1. Chen YY, You SL, Chen CA, et al. Taiwan Cervical Cancer Screening Task Force. Effectiveness of national cervical cancer screening programme in Taiwan: 12-year experiences. *Br J Cancer* 2009;101(1):174-7.
2. Shingleton HM, Bell MC, Fremgen A, et al. Is there really a difference in survival of women with squamous cell carcinoma, adenocarcinoma, and adenosquamous cell carcinoma of the cervix? *Cancer* 1995;76(10 Suppl.):1948-55. 62
3. Alfsen GC, Kristensen GB, Skovlund E, et al. Histologic subtype has minor importance for overall survival in patients with adenocarcinoma of the uterine cervix: a population-based study of prognostic factors in 505 patients with nonsquamous cell carcinomas of the cervix. *Cancer* 2001;92:2471-83.
4. Lee KB, Lee JM, Park CY, et al. What is the difference between squamous cell carcinoma and adenocarcinoma of the cervix? A matched case-control study. *Int J Gynecol Cancer* 2006;16(4):1569-73. 69
5. Eifel PJ, Burke TW, Morris M, et al. Adenocarcinoma as an independent risk factor for disease recurrence in patients with stage IB cervical carcinoma. *Gynecol Oncol* 1995;59:38-44.
6. Lai CH, Hsueh S, Hong JH, et al. Are adenocarcinomas and adenosquamous carcinomas different from squamous carcinomas in stage IB and II cervical cancer patients undergoing primary radical surgery? *Int J Gynecol Cancer* 1999;9:28-36.
7. Hong JH, Tsai CS, Wang CC, et al. Comparison of clinical behaviors and responses to radiation between squamous cell carcinomas and adenocarcinomas/adenosquamous carcinomas of the cervix. *Chang Gung Med J* 2000;23:396-404.
8. Huang YT, Wang CC, Tsai CS, et al. Long-term outcome and prognostic factors for adenocarcinoma/adenosquamous carcinoma of cervix after definitive radiotherapy. *Int J Radiat Oncol Biol Phys* 2011;80(2): 429-36.
9. Vizcaino AP, Moreno V, Bosch FX, et al. International trends in the incidence of cervical cancer: I.

- Adenocarcinoma and adenosquamous cell carcinomas. *Int J Cancer* 1998;75(4):536-45.
10. Pak SC, Martens M, Bekkers R, et al. Pap smear screening history of women with squamous cell carcinoma and adenocarcinoma of the cervix. *Aust N Z J Obstet Gynaecol* 2007;47(6):504-7.
 11. Sasieni P, Castanon A, Cuzick J. Screening and adenocarcinoma of the cervix. *Int J Cancer* 2009;125(3):525-9.
 12. Ashfaq R, Gibbons D, Vela C, et al. Accuracy for glandular disease. *Acta Cytol* 1999;43(1):81-5.
 13. Bai H, Sung CJ, Steinhoff MM. ThinPrep Pap Test promotes detection of glandular lesions of the endocervix. *Diagn Cytopathol* 2000;23(1):19-22.
 14. Cuzick J, Arbyn M, Sankaranarayanan R, et al. Overview of human papillomavirus-based and other novel options for cervical cancer screening in developed and developing countries. *Vaccine* 2008;26(Suppl. 10):K29-41.
 15. The American College of Obstetricians and Gynecologists. Clinical management guidelines for obstetrician-gynecologists-ACOG Practice Bulletin No. 109: cervical cytology screening. *Obstet Gynecol* 2009;114(6):1409-20.
 16. National Comprehensive Cancer Network Clinical Practice Guidelines in Oncology, Cervical Cancer-v.1. www.nccn.org/professionals/physician_gls/f_guidelines.asp 2006.
 17. Katanyoo K, Sanguanrungrasirikul S, Manusirivithaya S. Comparison of treatment outcomes between squamous cell carcinoma and adenocarcinoma in locally advanced cervical cancer. *Gynecol Oncol* 2012;125:292-6.
 18. Lee YY, Choi CH, Kim TJ, et al. A comparison of pure adenocarcinoma and squamous cell carcinoma of the cervix after radical hysterectomy in stage IB-IIA. *Gynecol Oncol* 2011;120:439-43.
 19. Park JY, Kim DY, Kim JH, et al. Outcomes after radical hysterectomy in patients with early-stage adenocarcinoma of uterine cervix. *Br J Cancer* 2010;102:1692-8.
 20. Kasamatsu T, Onda T, Sawada M, et al. Radical hysterectomy for FIGO stage I-IIB adenocarcinoma of the uterine cervix. *Br J Cancer* 2009;100:1400-5.
 21. Lee KB, Lee JM, Park CY, et al. What is the difference between squamous cell carcinoma and adenocarcinoma of the cervix? A matched case-control study. *Int J Gynecol Cancer* 2006;16:1569-73.
 22. Mabuchi S, Okazawa M, Matsuo K, et al. Impact of histological subtype on survival of patients with surgically-treated stage IA2-IIB cervical cancer: Adenocarcinoma versus squamous cell carcinoma. *Gynecol Oncol*. 2012 Article in press.

Curriculum Vitae

Present Title and Affiliation:

Chairman and Professor of Department of Obstetrics and Gynecology, Director of Gynecologic Cancer Center, College of Medicine, University of Ulsan, Asan Medical Center

Education and Certification:

1981	M.D. College of Medicine, Yonsei University, Seoul, Korea
1988	Specialty Board Certified, Obstetrician & Gynecologist
1991	Ph.D. Graduate School, Yonsei University

Postgraduate Training:

1981-1984	Military Service as an Army Surgeon
1984-1985	Rotating Internship in Yonsei Univ. Hospital
1985-1988	Residency in Obstetrics and Gynecology, Yonsei Univ. Hospital

● Topics 2-1-3

- 1994-1995 Fellowship at the Dept. of Pathology, Johns Hopkins University Hospital, Baltimore, Maryland, U.S.A.
- 2003-2004 Visiting Professor at the Dept. of OB&GYN Ohio State University, James Cancer Hospital

Academic and Administrative Appointments:

- 1989-Present : Professor, Department of Obstetrics and Gynecology, College of Medicine, University of Ulsan, Asan Medical Center, Seoul, Korea
- 1996-1998 : Secretary General, The Korean Society of Gynecologic Oncology and Colposcopy
- 2002 : Secretary General, IXth Biennial Meeting of International Gynecology Cancer Society (IGCS)
- 2002-2004 Cervical Cancer Committee Chair of KGOG
- 2004-2006 : Representative of Asia-Oceania in Nominating Committee of IGCS
- 2005- Secretary General, Asia Oceania Gynecologic Infection and Neoplasia (AOGIN)
- 2006- Council of Asia Oceania Federation of Obstetricians and gynecologists (AOFOG)
- 2006-2007 Senior Editor of International Journal of Gynecologic Cancer
- 2007-2008 Cervix Committee Member Gynecologic Oncology Group (GOG)
- 2009- Chairman of Scientific Committee of KSOG
- 2012- International Editorial Review Board of Taiwan Journal of OB/Gyn

Pathology of Sarcomas of the Uterus

Steven G. Silverberg

University of Maryland, Baltimore, USA

Uterine sarcomas are uncommon tumors, especially if one removes from this category carcinosarcoma (malignant mixed mesodermal tumor), which is now known to be in reality a metaplastic carcinoma. The two types of pure sarcoma most likely to be encountered by the gynecologic oncologist or pathologist are leiomyosarcoma and endometrial stromal sarcoma. Leiomyosarcoma is the most common uterine sarcoma, but its annual incidence is less than one per 100,000 women, which means that if a pathologist sees two benign myomatous uteri a day, he or she should find one leiomyosarcoma in a year, and about one “problematic” smooth muscle tumor (benign versus malignant) per month. These diagnostic problems will be discussed in detail.

Endometrial stromal tumors are classified as benign stromal nodule, (low grade) endometrial sarcoma, and undifferentiated uterine sarcoma (some but not all of which can be identified as high grade endometrial stromal sarcomas). Both stromal nodule and low grade stromal sarcoma are composed of small uniform cells with a distinctive vascular architecture, the difference between these two entities being the tumor/uterine interface, which is pushing in the stromal nodule and infiltrative in low grade ESS. High grade/undifferentiated sarcomas all have infiltrative borders, but by definition contain pleomorphic cells, usually with numerous mitotic figures (including atypical mitoses). LGESS generally contains progesterone receptors and is responsive to progestin therapy; the survival is close to 100% at five years, but late (up to 20-30 years) recurrences are common. The undifferentiated sarcomas, on the other hand, behave aggressively, with early recurrences and death (similar to leiomyosarcoma) and usual lack of response to hormonal therapy.

If time permits, adenosarcoma (a tumor composed of a benign glandular and a malignant stromal component, which behaves like a low grade sarcoma) and carcinosarcoma (which, as mentioned above, is really a carcinoma with a malignant metaplastic stromal element) will be discussed very briefly.

Curriculum Vitae

M.D. degree: Johns Hopkins, 1962

Pathology Residency: Yale, 1963-1965

Pathology Fellowship: Memorial Sloan-Kettering, 1965-1966

U.S. Air Force, Tachikawa Air Base Hospital, Japan, 1966-1968

Faculty Appointments:

Medical College of Virginia, 1968-1972

University of Colorado, 1972-1981

George Washington University, 1981-1996

University of Maryland, 1996-Present:

Director of Anatomic Pathology, and Director of Pathology Residency Program,

University of Maryland Medical System, Baltimore, 1996-2004;

● Topics 2-2-1

Clinical Professor of Pathology, 2004-2008
Professor Emeritus, 2008-Present

Honors (Selected):

President, International Society of Gynecological Pathologists (1998-2001), Association of Directors of Anatomic and Surgical Pathology (1998-2000), International Society of Breast Pathology (2003-2005).

Fellow, Royal College of Pathologists (1999)

Visiting Professor at numerous universities around the world over 30 years

Silverberg Award for Lifetime Achievement in Surgical Pathology—given to a senior Japanese Pathologist by the Japanese Division of the International Academy of Pathology since 2007

Recipient of Distinguished Pathologist Award, US-Canadian Academy of Pathology, 2012

Gynecologic Oncology Group, Pathology Referee, 1999-present

Does MRI help in Diagnosing Uterine Sarcomas?

Ting-Chang Chang

Department of Obstetrics and Gynecology, Chang Gung Memorial Hospital Linkou Medical Center, Taiwan

Owing to its rarity, non-specific presenting symptoms and insignificant findings on routine image, the diagnosis of uterine sarcoma prior to hysterectomy is difficult. The current World Health Organization classification of tumors of the female genital tract categorizes uterine mesenchymal tumors into smooth muscle and endometrial stromal tumors. Smooth muscle tumors composed of cells that show smooth muscle differentiation arising from the myometrium. They are divided into benign leiomyoma, smooth muscle tumor of uncertain malignant potential, and leiomyosarcoma (LMS). Endometrial stromal tumors arise from the endometrial stroma and include benign endometrial stromal nodule, endometrial stromal sarcoma (ESS), and undifferentiated endometrial sarcoma (UES). Carcinosarcoma (malignant mixed Mullerian tumor, MMMT) had traditionally been considered as a biphasic tumor, consisting of both carcinomatous epithelial and malignant mesenchymal components. It is now clear that both components derive from a single stem cell, with the epithelial element dominant in determining its biological behavior. MMMT has therefore been looked as an endometrial carcinoma with sarcomatous de-differentiation.

The importance of making a pre-operative diagnosis of uterine sarcoma such that appropriate surgery can be performed is increasing because of the current tendency towards the use of more conservative management of uterine fibroids. Uterine artery embolization, injection of gonadotrophic releasing hormone agonists may increase the risk of delayed diagnosis while morcellation at myomectomy or laparoscopic hysterectomy, or trans-cervical tumor resection may increase the risk of tumor spreading.

Though typical MRI patterns of uterine leiomyoma as well circumscribed low T1 and T2 signal tumor(s) have been described. Nevertheless, the difficulty is that current imaging modalities do not differentiate well between benign degenerating fibroids and malignant tumors, nor indeed distinguish the type among uterine sarcomas.

Recently, diffusion-weighted MRI, by utilizing the apparent diffusion coefficient (ADC) in differentiating between leiomyomas and malignant uterine tumours, has shown promise with the best sensitivity and specificity obtained by combining the ADC with T2-weighted MRI.

Change in endometrial stripe is more common in tumor arises from the endometrial gland, i.e., MMMT, than tumor arises from the endometrial stromal cells, and is least in leiomyosarcoma. Moreover, endometrial bleeding and abnormal discharge might be common and profound in MMMT but less common in ESS or LMS, though abnormal bleeding is still common in submucosal LMS and in ESS. Furthermore, MMMT is frequently diagnosed by endometrial curettage/biopsy but ESS and LMS may be missed diagnosed in curetted endometrial specimen.

With the aforementioned clinical characteristics in mind, we try to further realize if suspicion of an uterine sarcoma before surgery is beneficial to the patient's survival outcome and to develop a stepwise diagnostic

● Topics 2-2-2

flow for distinguishing uterine sarcomas from benign tumors through image studies, with special emphasis on MRI.

A retrospective collection of 90 cases with uterine leiomyosarcoma diagnosed at Chang Gung Memorial Hospital Linkou Medical Center 1990-2010 was used to test the aforementioned hypothesis and to validate the diagnostic flow.

Curriculum Vitae

Graduate Education:

1974-1981, China Medical University Medical College, Taichung, Taiwan
Degree-Bachelor of Medicine

Post-Graduate Education:

1990-1991, Harvard School of Public Health, Boston, Massachusetts, U.S.A.
Degree--Master of Public Health

Post-Doctoral Fellow:

1990-1991, Division of Gynecologic Oncology, Department of Obstetrics and Gynecology, Brigham and Women's Hospital and New England Trophoblastic Disease Center, Boston, Massachusetts, U.S.A.

Academic Appointment:

August 2008-present, Professor, Chang Gung University Medical College
July 2007-present, Academic Professor, Chang Gung Memorial Hospital
December 1999-July 2008, Associate Professor, Chang Gung University Medical College
July 1999-June 2007, Academic Associate Professor, Chang Gung Memorial Hospital

Employment Record:

August 2011-present, Vice Chairman, Department of Obstetrics and Gynecology, Chang Gung Medical Foundation Linkou Medical Center
September 2010-July 2011, Vice President, Xiamen Chang Geng Hospital, Xiamen, China
July 2007-July 2011, Director, Department of Obstetrics and Gynecology, Chang Gung Medical Foundation Linkou Medical Center
January 2007-June 2010, Director of Cancer Registration, Chang Gung Memorial Hospital Linkou Medical Center
December 2000-June 2007, Director, Section of Gynecologic Oncology, Department of Obstetrics and Gynecology, Chang Gung Memorial Hospital, Linkou Medical Center

Professional Activities:

President, Taiwan Association of Gynecologic Oncology, May 2010-May 2012
President, Taiwan Society of Cancer Registry, November 2006-October 2012
Chief Editor, National Consensus in Clinical Gynecologic Oncology, January 2003-Present
Secretary General, Taiwan Association of Gynecologic Oncology, 2002-2004

Recent Advances in Management of Uterine Sarcomas

Tadao Takano

Clinical Research, Innovation, and Education Center, Tohoku University Hospital, Japan

Uterine sarcomas are rare malignancies that differ in histologic appearance and in clinical behaviour. Uterine sarcomas may be classified as leiomyosarcomas, carcinosarcomas, endometrial stromal sarcomas, adenosarcomas, and high-grade undifferentiated sarcomas. Carcinosarcoma is considered by some to be a high-risk, de-differentiated variant of endometrial adenocarcinoma.

For high-grade leiomyosarcomas, the risk of recurrence is high after complete resection of uterus-limited disease; however, no adjuvant therapy has been proven to improve survival. The role of adjuvant chemotherapy in completely resected, uterus-limited leiomyosarcoma should be addressed in a prospective phase III trial with a no-chemotherapy control arm in order to determine whether chemotherapy can improve progression-free, overall survival, or both.

Active agents in metastatic uterine leiomyosarcoma include doxorubicin, ifosfamide, and fixed-dose rate gemcitabine plus docetaxel.

The Gynecologic Oncology Group is conducting a phase III placebo-controlled trial to determine whether the addition of bevacizumab to fixed-dose rate gemcitabine plus docetaxel improves response rates or progression-free survival in advanced uterine leiomyosarcoma.

Uterine carcinosarcomas also have a high risk for recurrence. Adjuvant dual-agent chemotherapy is a standard approach to treatment of completely resected uterine carcinosarcomas. Active chemotherapy regimens for uterine carcinosarcoma include ifosfamide plus cisplatin, ifosfamide plus paclitaxel, and carboplatin plus paclitaxel. The current Gynecologic Oncology Group study for completely resected carcinosarcoma is a phase III comparison of ifosfamide plus paclitaxel versus paclitaxel plus carboplatin.

The Gynecologic Oncology Group is currently studying pazopanib in a phase II trial.

Curriculum Vitae

Education and professional training

- 1983 Graduated from Sendai First High School
- 1990 Graduated from Tohoku University
M.D. Japanese Medical License Registration (NO. 330745)
Resident in Tohoku University Hospital
- 1991 Medical Staff, OB/GYN, Hiraka General Hospital, Yokote, Akita
- 1993 Medical Staff, OB/GYN, Tohoku University Hospital
- 1998 Ph.D. Tohoku University
Medical Staff, OB/GYN, Ohta-Nishinouchi General Hospital, Koriyama, Fukushima
- 2003 Assistant Professor, OB/GYN, Tohoku University Hospital
- 2010 Director of perinatal center, Hachinohe City Hospital, Hachinohe, Aomori
- 2010 Assistant Professor, Translational Research Center, Tohoku University
- 2012 Professor, Clinical Research, Innovation, and Education Center, Tohoku University Hospital (CRIETO)

Japan society of obstetrics and gynecology member

Japan society of gynecologic oncology member

ASCO member

ESGO member

Histotype-specific Genomics Alterations in Ovarian Cancer

Liang Kee Goh

Cancer & Stem Cell Biology, Duke-NUS Graduate Medical School, Singapore

Epithelial ovarian cancer is characterized by multiple genomic alterations; most are passenger alterations which do not confer tumor growth. Like many cancers, it is a heterogeneous disease and can be broadly categorized into 4 main histotypes of clear cell, endometrioid, mucinous, and serous. To date, histotype-specific copy number alterations have been difficult to elucidate. The difficulty lies in having sufficient sample size in each histotype for statistical analyses. To dissect the heterogeneity of ovarian cancer and identify histotypes-specific alterations, we used an *in silico* hypothesis-driven approach on multiple datasets of epithelial ovarian cancer. In concordance with previous studies on global copy number alterations landscape, our study showed similar alterations. However, when the landscape was de-convoluted into histotypes, distinct alterations were observed. We report here significant histotype-specific copy number alterations in ovarian cancer and showed that there is genomic diversity amongst the histotypes. 76 cancer genes were found to be altered where majority were found in serous histotypes. Several genes are potential drivers, including ERBB2 in mucinous, BRAF in serous, and TPM3 in endometrioid histotypes. ERBB2 is found to have preferential alterations, where it is significantly amplified in mucinous (26.3%) but deleted in serous tumors (15%). Validation of ERBB2 support its potential as a copy number driver gene in ovarian cancer. We also observed reciprocal relationship between KRAS mutation and copy number alterations. In mucinous where KRAS mutation is common, the gene is not significantly altered. Our study demonstrates that it is possible to combine multiple datasets to identify histotype-specific copy number alterations. Identification of these alterations can pave the way for targeted drug therapy specific to the histotypes.

Curriculum Vitae

Dr GOH Liang Kee is an assistant professor in the Cancer & Stem Cell Biology Program at Duke-NUS Graduate Medical School. She holds joint appointment in Saw Swee Hock School of Public Health and is also a visiting scientist at the Department of Medical Oncology, National Cancer Centre Singapore. Her research interests are in computational biology, using statistical and machine learning approaches to elucidate underlying molecular aberrations in diseases and drug responses. Her lab focused on high-throughput genetics and genomics analyses; elucidating biomarkers and/or molecular aberrations for translational medicine. She has developed methodologies to elucidate molecular aberrations from high-throughput data including DNA methylation, copy number alterations, SNPs, gene expression, and next-generation sequencing. The focus is on translational science; making discoveries and translating into practical clinical applications.

The Prognostic and Therapeutic Potential of AMP-activated Protein Kinase in Ovarian Cancer

David W Chan, Hextan YS Ngan

Department of Obstetrics and Gynecology, LKS Faculty of Medicine, The University of Hong Kong, Hong Kong SAR, P.R.China

Ovarian cancer is one of the leading causes of cancer-associated death in women. The high mortality is due to its poor prognosis as most cases are found in late stages. Therefore, searching reliable tumor markers is urgently needed for clinical management of this disease. Altered cellular metabolism is a crucial phenomenon for the development and progression of ovarian cancer. AMP-activated protein kinase (AMPK) acts as a key intracellular energy sensor and regulator for governing energy balance homeostasis. It also closely links with cancer cell metabolism. Others and we have reported that the activation of AMPK by pharmacological agents shows cytotoxicity to cancer cells, indicating that targeting AMPK could be a promising therapeutic approach. On the other hand, our study also demonstrated that the AMPK activity had an inversely correlation between tumor stage and/or high grade ovarian cancer. Importantly, the reduced AMPK activity was associated with the increased ERK/FOXO1 signaling cascade in advanced ovarian cancers. The ERK/FOXO1 signaling pathway has been shown to possess oncogenic effects on promoting oncogenesis in numerous human cancers and showed a progressive increased pattern from low- to high-grade tumor. In fact, using ovarian cancer cell models, we showed that the activation of AMPK by pharmaceutical or natural AMPK activators could inhibit not only ERK/FOXO1 activity but also the tumor growth. The suppressive functions were equivalent to ERK or FOXO1 inhibitors in ovarian cancer cells or other gynecological carcinoma cell lines. Taken together, these findings suggest that the decreased AMPK activity may act as a prognostic marker in ovarian cancer because it is significantly correlated with the increased ERK/FOXO1 signaling cascade and the advanced stage ovarian cancers. Moreover, targeting AMPK by either pharmaceutical or natural AMPK activators may be explored as an alternative therapeutic regimen in the treatment of this disease.

Curriculum Vitae

Academic Qualifications: BSc. (Hons) (HKBU) 1992, MPhil (HKU) 1996, PhD (Monash) 2002

Present Academic Position: Research Assistant Professor, Honary Assistant Professor
Department of O & G, HKU, 2007-present

Previous relevant research work:

2006-2007	Postdoctoral Fellow and Hon. Assistant Professor, Dept. of O&G, HKU.
2003-2006	Postdoctoral Fellow, Department of Pathology, HKU.
2001-2003	Research Officer, Peter MacCallum Cancer Institute, Uni. of Melbourne.
2000-2001	Research Officer, MIRD, Monash University.
1996-1997	Technician, Department of Medicine, HKU.

● Topics 3-2

1995-1996 Research Assistant I, Department of Microbiology, HKU.
1992-1994 Research Assistant II, Department of Medicine, HKU.

Research Interest:

1. Functional characterization of novel oncogenes and tumor suppressor genes and delineation of the related cellular signaling pathways such as ERK, Hedgehog and Wnt/ β -catenin which contribute to the tumorigenesis of gynaecological malignancies.
2. To examine the role of miRNAs in the development of chemoresistance and metastasis in ovarian cancer.
3. To understand the underlying molecular mechanisms associated with cancer cell metabolism and tumor microenvironment in ovarian cancer.

Current funded projects:

1. Functional Characterization of Has-miR-141, a Putative Oncogene in Promoting Anchorage-Independent Growth Ability of Ovarian Cancer Cells
2. The functional impact of AMP-activated protein kinase gamma-2 (AMPK- γ 2) subunit expression on AMPK activity and oncogenesis in ovarian cancer
3. Functional characterization of GRB7 and its variant, GRB7v, in ovarian cancer
4. Potential interaction between Zic2 and Gli proteins in enhancing the oncogenic role of hedgehog signaling in cervical cancer
5. Characterization of the roles of Dual specificity MAPK phosphatase 3 (MKP-3) in ovarian cancer

The Role of Aberrant MiR-196a Expression In HPV Positive Cervical Cancer

Chunling Chen, Chanzhen Liu

Department of Obstetrics and Gynecology, Beijing Royal Intergrative Medicine Hospital, China

MicroRNAs (miRNAs) play a pivotal role in many aspects of cell biological processes. Aberrant miRNA expression in human being is becoming recognized as a new molecular mechanism of carcinogenesis and tumor progression. In our previous study, the reduction of microRNA-196a (miR-196a) expression was not only detected in cervical tissues, but also in HPV16 infected cervical tissues. It implied a special role of miR-196a in HPV16 infected cervical cancer. In this study, the expression of miR-196a in different cervical tissues and four cervical cancer cell lines were screened through quantitative real-time RT-PCR. After that, we successfully regulated the basal level of miR-196a in cells with miRNA inhibitor or miRNA mimics and then assessed the effect of miR-196a on cell malignant phenotype by examining cell proliferation, cell cycles, apoptosis, migration and invasion. The results indicated that miR-196a was down-regulated in pre-malignant HPV16 infections, cervical cancer tissues, and HPV16 positive cervical cancer cells lines. MiR-196a inhibited proliferation and growth of cervical cancer cells, induced G0/G1 arrest and blocked the progression from the G1 to S phase, maintained cell apoptosis and showed some tumor suppressive feature in cervical cancer. To date, this is the first study on the biological function of miR-196a in cervical cancer. MiR-196a is a potential tumor suppressor in cervical cancer.

Curriculum Vitae

Professor, Obstetrics and Gynaecology

Secretary, Chinese Society of Gynaecologic Oncology

Director, Editorial Department of International Journal of Gynecological Cancer (Chinese edition)

Vice Chief Editor, International Journal of Gynecological Cancer (Chinese edition)

Vice Director, Beijing Royal Hospital

Dr Chen graduated from Hong Kong University with a doctor's degree of gynecologic oncology in 2001 and subsequently received gynecologic oncology training at the Affiliated Hospital of Oxford Medical School, and Italy National Cancer Hospital. She specializes in gynecologic oncology surgery and gynecological laparoscopic surgery. Also proficient with the diagnosis and treatment of CIN and the pain related to gynaecologic disease. Her research orientation includes Epigenetic Regulation In Gynecological Cancer; Chemoresistance in Ovarian Cancer; Cervical cancer transformation; Psychosocial investigation and intervention in gynecological cancer patients. Dr.Chen took charge the translation of Williams Gynecology (Chinese version) in 2010 and is the subeditor of Chinese Obstetrics and Gynecology (Clinical version).

Biology of Ovarian Clear Cell Carcinoma: Microarray Analysis and Bioinformatics

Noriomi Matsumura

Department of Gynecology and Obstetrics, Kyoto University Graduate School of Medicine, Kyoto, Japan

Purpose/Background: Ovarian clear cell carcinoma (OCCC), a chemoresistant subtype of ovarian cancer, has rapidly increased in Japan during the last 30 years. Traditionally, the standard chemotherapeutic regimen, containing taxane and platinum, has been used against any type of ovarian cancer. There is an urgent need for developing a novel modality of therapy against chemoresistant subtypes like OCCC. The purpose of this research was to identify a novel molecular target therapy against OCCC based on microarray analysis using bioinformatics.

Methods/Approaches: Expression microarray of 38 ovarian cancer cell lines, including 13 OCCC lines was performed using Affymetrix U133A GeneChip. This microarray data and other publicly available microarray datasets were analyzed to predict an effective drug against OCCC. Finally, in vivo anti-tumor effect of the predicted drug against OCCC cell line RMG-2 was analyzed.

Results/Perspectives: "OCCC signature", differentially expressed 320 genes between OCCC and non-OCCC subtypes of ovarian cancer, was identified using both cell line and clinical tissue datasets. The OCCC signature reproducibly detected OCCC in two external microarray datasets. Hierarchical clustering analysis and principal component analysis indicated that OCCC is strikingly similar to renal cell carcinoma based on the gene expression profile. Furthermore, pathway analyses with binary regression detected activated RAS and suppressed E2F signal activity. Therefore, sorafenib, a multikinase inhibitor, which was recently approved for renal cell carcinoma, was predicted to be effective against OCCC. Orally administered sorafenib (40 mg/kg/day) showed marked anti-tumor effect against RMG-2 inoculated subcutaneously on nude mice ($p < 0.001$). On the other hand, intraperitoneal injection of cisplatin (5mg/kg/week) did not show in vivo anti-tumor effect against RMG-2. Therefore, sorafenib is promising against OCCC.

Curriculum Vitae

10 July 1971	Born in Hyogo, Japan
April 1990-March 1996	Faculty of Medicine, Kyoto University
May 1996-April 1998	Resident in Kyoto University Hospital, Department of Obsterics and Gynecology
May 1998-March 2000	Medical Staff in Hyogo Prefectural Amagasaki Hospital
April 2000-August 2002	Medical Staff in Toyooka Public Hospital
September 2002-March 2003	Medical Staff in Kyoto University Hospital
April 2003-March 2007	Graduate School of Medicine, Gynecology and Obstetrics, Kyoto University
April 2005-March 2007	Research associate in Duke University Medical Center, Gynecologic Oncology
March 2007	Doctor's degree in Gynecology and Obstetrics, Kyoto University
April 2007-	Assistant Professor, Kyoto University

Abdominal Radical Trachelectomy

Tadayoshi Nagano

The Tazuke Kofukai, Medical Research Institute, Kitano Hospital, Osaka, Japan

In 1987, D'Argent et al designed an operation called radical vaginal trachelectomy (RVT) known as the D'Argent operation. VRT was originally recommended for up to stage Ia2 patients, and it was also reported that a size limit of up to 2 cm in diameter was considered safe for stage Ib1 cases. However, VRT is limited by the resectable size of the parametrium because of the narrowness of the vagina. To resect parametrium more widely and more safely, abdominal radical trachelectomy (ART) was proposed by Smith JR et al in 1997.

As ART is similar to a standard radical hysterectomy, it seems to be more acceptable in general. In fact, questionnaire survey revealed that trachelectomy performed in Japan was mainly ART.

From November, 2005, through March 31, 2012, 38 women with stage I carcinoma of the cervix were undergo radical trachelectomy in our institute. We basically tried to preserve bilateral uterine arteries and bilateral pelvic nerve plexus. Cervical cerclage was performed intra-operatively. Our ART procedure will be presented by movie.

Abdominal radical trachelectomy, combined with pelvic lymphadenectomy, can be a feasible method of treatment for early-stage cervical carcinoma in women who want to preserve their fertility.

Curriculum Vitae

1973-1979 ;	Hyogo Medical College
1979-1980 ;	Graduate school of Hyogo Medical College
1980-1984 ;	Resident of Osaka National Hospital
1984-2005 ;	Medical staff of Ob/Gyn, Osaka National Hospital
2005-2007 ;	Assistant director of Dept of Ob/Gyn, KITANO Hospital
2007-present ;	Director of Dept of Ob/Gyn, KITANO Hospital, Osaka, JAPAN

Cytoreductive Surgery for Advanced Ovarian Cancer

Sang-Yoon Park

National Cancer Center, Korea

The incidence of ovarian cancer rapidly increase nowadays due to the changing of the life style to western country in Korea. The number of ovarian cancer registration increase 40% during last 10 years (1297 in 1999, 1783 in 2009). Ovarian cancer is most important disease among female genital cancers at my office, because of not only rapidly increasing disease, but also it needs long term treatment in compare to cervical cancer and corpus cancer, and the majority of patients with newly diagnosed ovarian cancer present with advanced-stage disease, and it shows frequent recurrence. So, more than 60% of my in patients and out patients are ovarian cancer.

Ovarian cancer is most interesting disease, because it shows survival difference according to institutional and physician's policy. There are several prognostic factors such as stage, age, ascites, performance status, pathologic type, genetic alteration, chemosensitivity, postoperative residual tumor size, et al in the management of ovarian cancer. These factors are unchangeable except postoperative residual tumor size when physicians manage the patients.

Advanced epithelial ovarian cancer typically presents with widely disseminated intra-abdominal disease. The standard treatment of advanced epithelial ovarian cancer (EOC) includes primary cytoreductive surgery followed by adjuvant systemic chemotherapy. The goal of primary surgery for advanced epithelial ovarian cancer is to accurately establish a diagnosis and leave little or no residual disease. Although there are no randomized controlled trials supporting cytoreductive surgery, nearly every retrospective and prospective study has demonstrated an inverse relationship between residual tumor diameter and patient survival, including a recent meta-analysis by Bristow and colleagues, which showed that each 10% increase in maximal cytoreduction was associated with a 5.5% increase in median survival.

Extensive upper abdominal surgery

A substantial number of patients with advanced-stage ovarian cancer present with bulky upper abdominal disease, malignant pleural effusions, or even intraparenchymal liver disease and may require diaphragmatic or intestinal procedures, splenectomy with or without a distal pancreatectomy, and peritoneal stripping to achieve an optimal cytoreduction. Recent data demonstrate the technical feasibility of ultra-radical surgery and the significant survival advantage afforded by optimal tumor removal even in stage IV patients. Surgery for ovarian cancer requires that the abdominal incision be adequate to explore the entire abdominal cavity and allow safe cytoreductive surgery. Any ascites or free peritoneal fluid should be collected for cytology. If no free peritoneal fluid is present, separate peritoneal washings can be obtained from the pelvis, paracolic gutters, and infradiaphragmatic area. Patients with stage III or IV disease do not require cytologic assessment. All peritoneal surfaces including the surface of both diaphragms and the serosa and mesentery of the entire gastrointestinal tract should be visualized and palpated for evidence of metastatic disease with careful inspection of the omentum and removal, if possible. Splenectomy, distal pancreatectomy, liver resection, resection of tumor from porta hepatis, supra-renal LND, cholecystectomy, total colectomy, pelvic

peritonectomy, diaphragmatic stripping and/or resection should be tried to attain minimum residual disease as an extensive upper abdominal surgery. Sometimes VATS (video assisted thoracoscopic surgery), wedge resection of stomach, pelvic bone resection, abdominal wall resection may be needed.

Colon resection and peritonectomy for pelvic disease

One of the initial expansions in radical ovarian cancer surgery was the removal of the uterus, both ovary, and rectosigmoid colon, either separately or en bloc, in order to clear the pelvis of tumor. The rectosigmoid is the most frequently resected segment of colon in ovarian cancer surgery. The descriptive classification system has been applied to radical gynecologic operation in ovarian cancers by Eisenkop. Type I radical operation consists of a retrograde modified radical hysterectomy with en bloc resection of the adnexa, pelvic cul-de-sac tumor, and involved pelvic peritoneum. Type II radical operation is broadened to include an en bloc resection of the rectosigmoid colon below the peritoneal with complete parietal and visceral pelvic peritonectomy. Finally, the type III radical oophorectomy is an extension of the type I or II procedure incorporating a portion of urinary bladder and/or pelvic ureter.

At this time, complete cytoreduction continues to be, when feasible, the objective to be attempted in the surgical treatment of advanced ovarian cancer. In a significant number of cases, complete cytoreduction involves complex surgical procedures, which require the availability of a dedicated multispecialty surgical team. In order to offer patients the best possible outcome, with the least accompanying morbidity, strong consideration should be given for the referral of such patients to high-qualified care centers.

I would like to present our experiences with cytoreductive surgery as a part of the primary cytoreductive surgery for advanced ovarian cancer with respect to operative procedures and clinical outcomes.

Curriculum Vitae

Present Title : Chief, Center for Uterine Cancer
National Cancer Center Korea
Gyeonggi, Korea

EDUCATION

1973-1979 M.D.; Medical College of Seoul National University, Seoul, Korea
1989-1991 Ph.D.; Medical College of Korea University, Seoul, Korea

POSTGRADUATE TRAINING:

1980-1983 Residency; Department of Ob. & Gy., Seoul National University Hospital, Seoul, Korea
1987-2000 Director; Department of Ob & Gy, Korea Cancer Center Hospital, Seoul, Korea
1991-1992 Postdoc Fellow; Department of Ob. & Gy., Yale University, New Haven, CT, USA
1997. 7 Visiting Doctor; Department of Surgical Oncology, Washington Cancer Center
1997. 8 Visiting Doctor; Department of Ob. & Gy., Mainz University, Germany
2000-Present Chief, Uterine Cancer Branch, National Cancer Center, Go-yang, Korea

Laparoscopic Surgery for Gynecological Cancer

Kung-Liahng Wang

Mackay Memorial Hospital, Taipei, Taiwan

It is clear that gynecologic oncologists can manage gynecologic cancers after more than twenty years of experience with laparoscopic procedures. More and more gynecological surgeons employed laparoscopic procedure for the management of gynecological malignancy. Today, laparoscopic surgery refers to a minimal invasive procedure of the abdomen that gains access to a very focal area without a large incision and renders a minimal formation of scar tissue. Many patients with gynecologic cancers may benefit from laparoscopic radical hysterectomy, laparoscopic staging, evaluation, or a combination of them. The intraoperative benefits of the laparoscopic technique include minimal blood loss, less adhesion formation and better visual perspective. Surgical staging by laparoscopy is certainly attractive to patients with advanced disease in that they can avoid a laparotomy before initiating definitive chemotherapy and irradiation. There is no question that the complication rate of laparoscopic surgeries is extremely low in the hands of experienced gynecological oncologists. It has become a popular and widespread technique accepted by gynecologists as an appropriate alternative to conventional surgery in the management of patients with gynecologic cancers.

Curriculum Vitae

PRESENT TITLE AND AFFILIATION:

Chairman, Department of Obstetrics and Gynecology, Mackay Memorial Hospital (2008-now)
 President, Taiwanese Gynecologic Oncology Group (2009-now)
 Council Member, Asian Society of Gynecologic Oncology (2009-now)
 Associate professor, Department of Health Care Management, National Taipei College of Nursing (2009-now)
 Associate professor, Department of Nursing, Mackay Medicine, Nursing and Management College (2009-now)
 Past-President, Taiwan Association of Gynecologic Oncologists (2008-2010)
 Past-President, The Society of Gynecologic Oncology, R.O.C.(Taiwan) (2008-2010)

EDUCATION:

1973-1980 M.D. Department of Medicine, Kaohsiung Medical University, Kaohsiung, Taiwan
 2000-2002 Institute of Hospital and Health Care Administration, School of Medicine, National Yang-Ming University, Taipei, Taiwan

POSTDOCTORAL TRAINING:

1. Internship Kaohsiung Medical University Hospital, Kaohsiung, Taiwan
 1979-1980
 2. Military service Medical officer, Taiwan Army
 1980-1982
 3. Residency Department of Obstetrics and Gynecology, Mackay Memorial Hospital, Taipei, Taiwan
 1982-1986
 4. Fellowship Department of Gynecologic Oncology, University of Texas, M.D. Anderson Cancer Center, Houston, Texas, USA
 1990-1991

Robotic Surgery for High Risk Endometrial Cancer

John Fletcher Boggess

Department of Obstetrics and Gynecology, Division of Gynecologic Oncology, University of North Carolina, Chapel Hill, NC, USA

Endometrial cancer remains the most common gynecologic cancer in the United States with more than 40,000 cases annually. Most women with endometrial cancer are obese and have medical comorbidity, which contribute to surgical risk. Laparoscopy has decreased surgical morbidity in women with endometrial cancer significantly by eliminating wound complications and bowel complications. In addition, hospital stay, blood loss, and recovery have all been reduced. Laparoscopic tools do have their limitations, however, particularly in very obese women. It is estimated that after more than 30 years of video laparoscopy, only 20% of women in the United States with endometrial cancer are treated laparoscopically.

Robotic assisted surgery was introduced in 2001 where it was first applied to cardiac and then urologic surgery. In 2005 the DaVinci robotic surgical system received FDA approval for gynecologic surgery. Since then, our institution pioneered techniques for staging women with endometrial cancer and has published several series documenting feasibility and benefit over laparoscopy. It is estimated that over 60% of endometrial cancer patients in the United States were staged with robotic assistance in 2011. The rapid adoption of robotic assisted surgery in endometrial cancer treatment is attributed to the advantages of 3D vision, wristed instruments and improved ergonomics.

It is very important to establish a standardized approach to staging endometrial cancer robotically. We have developed such a standard technique, which has resulted in a generalizable and effective surgically staging method to treat endometrial cancer. This video presentation will highlight our technique.

Curriculum Vitae

Certification and Licensure

2001	Diplomate Specialty–Gynecologic Oncology American Board of Obstetrics and Gynecology
1999	Diplomate American Board of Obstetrics and Gynecology
1995	Licensed North Carolina, Number 95-01179
1992	Diplomate National Board of Medical Examiners

Education–Postgraduate Training, Fellowships, Residencies, and Traineeships

1995–1998	Fellowship	Division of Gynecologic Oncology Department of Obstetrics and Gynecology
-----------	------------	---

● Topics 5-1

		University of North Carolina at Chapel Hill Chapel Hill, North Carolina
1991–1995	Residency	Department of Obstetrics and Gynecology University of Washington Seattle, Washington
1987–1991	Medical School	Oregon Health Sciences University School of Medicine Portland, Oregon Doctor of Medicine
1982–1986	College	University of California, Irvine Irvine, California Bachelor of Science, Biology

Professional Experience

2005 to present	Associate Professor, with tenure Division of Gynecologic Oncology Department of Obstetrics and Gynecology University of North Carolina at Chapel Hill Chapel Hill, NC
1998 to 2005	Assistant Professor Division of Gynecologic Oncology Department of Obstetrics and Gynecology University of North Carolina at Chapel Hill Chapel Hill, NC
1995 to 1998	Clinical Instructor Division of Gynecologic Oncology Department of Obstetrics and Gynecology University of North Carolina at Chapel Hill Chapel Hill, NC

Honors and Awards

2011	Healthcare Heroes of the Triangle: Healthcare Innovator
2008–2011	Best Doctors of America
2007	CREOG National Faculty Teaching Award American College of Obstetrics & Gynecology
2007	Person of the Year Blue & White Magazine, University of North Carolina at Chapel Hill
2005	Golden Tarheel Faculty Teaching Award University of North Carolina at Chapel Hill
2003	Valerie M. Parisi Excellence in Teaching Award University of North Carolina at Chapel Hill
2000	Association of Professors of Gynecology and Obstetrics Excellence in Teaching Award University of North Carolina at Chapel Hill
1999	Association of Professors of Gynecology and Obstetrics Excellence in Teaching Award University of North Carolina at Chapel Hill

- 1999 **Dean's Award for Teaching Excellence**
University of North Carolina School of Medicine
University of North Carolina at Chapel Hill
- 1995 **Ortho Pharmaceutical Ob/Gyn Chief Resident**
Award for Teaching Excellence
University of Washington
- 1991 **Cum Laude**
Oregon Health Sciences University/School of Medicine
- 1991 **William R. Krippaehne, M.D., Student of Surgery Award**
Oregon Health Sciences University/School of Medicine
- 1990 **Alpha Omega Alpha, Medical Honor Society(elected)**
Oregon Health Sciences University/School of Medicine

Robotic Radical Hysterectomy for Cervical Cancer

Yoon Soon Lee

Gynecologic Cancer Center, Kyungpook National University Medical Center, Daegu, Korea

Radical hysterectomy is standard treatment for patients with early-stage cervical cancer.

In the past two decades, the gynecologic oncologic surgeons performed minimally invasive techniques in order to decrease morbidity while maintaining surgical and oncological outcomes. Many studies showed the safety and feasibility of laparoscopic radical hysterectomy for the treatment of early-stage cervical cancer. Laparoscopic radical hysterectomy was not widely adopted in surgical practice, probably due to very difficult to do by limited movement of instrument.

Robot-assisted technique through the da Vinci Surgical System emerged in minimally invasive surgery to overcome disadvantages of conventional laparoscopy. In these days, surgical techniques and indications of Radical hysterectomy were different between east and western countries. Robotic system has several advantages such as, more stable operative surgical views in delicate dissection, especially deep in the cardinal ligament and vesicouterine ligament, identify the branches of hypogastric vessel and more stable in laparoscopic view the deep in pelvis, especially the inferior hypogastric plexus. To reduce ureter injury it needs careful manipulation of ureter in learning period. Moreover robot can dissection in blind area of laparoscopy, such as left presacral, post. part of hypogastric vessel, gluteal lymph node and to identify Sacral nerve S1, S2, S3, lumbosacral trunk, sup. hypogastric plexus and hypogastric nerves.

In this lecture we demonstrate our techniques of conventional nerve sparing RoRH and extended lymphadenectomy with Sup.Hypogastric Plexus sparing.

Curriculum Vitae

Current appointment (position and institution):

Professor

Dep. of Ob & GY, Kyungpook national university, Graduated school of medicine, Daegu, Korea.

Chief of Gynecologic cancer center

Academic degree (title and year obtained):

M.D. 1980

Special board of Korean Obstetric and Gynecology; 1984

PhD, 1991

Member of Korean society of Ob & GY

Member of Korean society of Gynecologic Oncology and colposcopy

Member of Korean society of Gynecologic Endoscopy

Member of Korean society of Urogynecology

Member of American Association of Gynecologic Laparoscopist

Field of specialization:

Gynecologic Oncology

Gynecologic Endoscopy
Gynecologic Robotic Surgery

Short scientific biography:

- 1999. July ; Visiting Professor at Dep. of Gynecologic oncology, Friedrich Schiller University, Jena, Germany
- 1996-1998 ; Research fellow in Washington University, Department of gynecologic oncology, St. Louis. USA
- 2000 to present ; Professor in Kyungpook national university, school of medicine
- 1997-2000 ; Associated professor in Kyungpook national university, school of medicine
- 1993-1997 ; Assistant professor in Kyungpook national university, school of medicine

Fertility-sparing Robotic assisted Radical Trachelectomy in Early-Stage Cervical Cancer

Young Tae Kim

Division of Gynecologic Oncology, Department of Obstetrics and Gynecology, Institute of Women's Life Medical Science, Yonsei University College of Medicine, Seoul, Korea

Background: For patients with cervical cancer which have invaded 3 mm or deeper into the cervical wall (FIGO stage IA2 or higher), radical hysterectomy (RH) and radiotherapy are standard treatments. Cancer-related infertility in young female patients receiving standard treatments for gynecologic malignancies lead to problems such as depression, grief, stress, and sexual dysfunction. Radical trachelectomy is an established method to preserve fertility in patients with early-stage cervical cancer. However, this technique requires very advanced vaginal surgery skills not commonly acquired. In an attempt to simplify the procedure, we performed robotic-assisted radical trachelectomy and pelvic lymph node dissection in patients with early-stage cervical cancer.

Cases and surgical technique: This presentation illustrates 8 cases (FIGO stage IB1-IIA1) where robotic-assisted radical trachelectomy and pelvic lymph node dissection were performed. The Da Vinci Surgical System (Intuitive Surgical, Inc., Sunnyvale, California) was used with a camera port, 2 robotic instrument ports, and 1 assistant port. The entire procedure is accomplished with bipolar Maryland forcep and monopolar scissor. Entering abdominal cavity, the parametria, paracolpium and sacrouterine ligaments were dissected sparing the ascending branches of the uterine arteries. After the descending branches of the uterine vessels were cauterized at the isthmus of the uterus and cervix, the cervix and the vagina were transected using monopolar scissor. The vagina was sutured to the remaining cervix. The median operation time and the median console time were 266.5 (range; 194-379) and 228 (range; 194-379) min respectively. The median hemoglobin change in postoperative day 1 was 2.4 (range; 1.3-4.2) g/dL, and only one case of transfusion was reported. No perioperative complications were noted. The median postoperative hospital stay was 10 (range; 7-14) days. Postoperative complications included 1 case of urinary tract infection and 5 cases of fever ($>38.0^{\circ}\text{C}$) on postoperative day 1.

Conclusions: The robotic-assisted radical trachelectomy and pelvic lymph node dissection is a safe and feasible alternative to a combined laparoscopic and vaginal approach. Although the main advantage of trachelectomy lies in its ability to preserve fertility, long-term obstetrical outcomes must be evaluated owing to short follow-up periods.

Curriculum Vitae

EDUCATION AND PREVIOUS TRAINING:

Mar. 1980	Premedical Course, Yonsei University
Feb. 1982	College of Science and Engineering, Seoul, Korea
Mar. 1982	M.D. degree from Yonsei University College of Medicine
Feb. 1986	Seoul, Korea

Mar. 2007 Professor & Director of Obstetrics and Gynecology
Present Yonsei University College of Medicine, Seoul, Korea

HONORS:

FIGO/Chein-Tien Hsu Fellowship Award (Gynecologic Oncology)

XV FIGO World Congress of Gynecology and Obstetrics (1997)

Copenhagen, Denmark (\$5,000)

Title; Expression of epidermal growth factor receptor(EGFR) and c-erbB-2 oncoprotein in carcinoma of the cervix.

32th Yuhan Medical Science Award

Seoul Medical association (1999)

Seoul, Korea (\$5,000)

Title; Underexpression of cyclin-dependent kinase (CDK) inhibitors in cervical carcinoma

9th Young Scientist Award

9th Biennial Meeting of the International Gynecologic Cancer Society

Seoul, Korea (2002) (\$2,000)

Title; Expression of cyclin E in placentas with hydropic change and gestational trophoblastic diseases

HPV Vaccination in Asia: Globalization of Combat against Cervical Cancer

Sarikapan Wilailak

Department of Obstetrics and Gynecology, Faculty of Medicine, Ramathibodi Hospital, Mahidol University, Bangkok, Thailand

Human papillomavirus (HPV) is the cause of 99% of all cervical cancers and is sexually transmitted. Cervical cancer, although highly treatable with early detection, remains the leading cause of cancer deaths among women especially in developing countries. Over half of the world's cervical cancer cases and deaths occur in the Asia-Pacific region. Among and within nations of this region, substantial variations in cervical cancer incidence and mortality exist.

The development of HPV vaccine which has shown to be highly effective in preventing infections that cause at least 70% of all cervical cancers, represents a major breakthrough for women's health. Widespread availability in most industrialized countries can almost be taken for granted, but most women living in the developing world will have to wait for sometime for several reasons. Unlike traditional vaccines, whose impact is measurable in the short term, the HPV vaccine will be administered to young adolescents to prevent illnesses and deaths that could be expected to occur some 30 years later. To combat against cervical cancer in each country, it advocates that firstly, government makes cervical cancer a priority in the national health plans. Secondly, medical professionals become educated and inform their patients/population about the availability of HPV vaccine along with cervical cancer screening. Thirdly, manufactures ensure adequate supplies of these technologies in a tiered pricing structure that allows poor countries to provide access in the public sector. Fourthly, the international organization/donors commit the resources to get this vaccine to the people who need it most as soon as possible. And finally, civil society groups coalesce and catalyze national/regional/global action. Situation analysis of HPV vaccination among countries in Asia will be discussed.

Curriculum Vitae

Dr. Sarikapan Wilailak is a Professor and Chairman of the Department of Obstetrics and Gynecology, Ramathibodi Hospital, Mahidol University, Bangkok, Thailand. She earned a medical degree from Faculty of Medicine, Chulalongkorn University, Bangkok, Thailand and received a Thai Board Diploma of Obstetrics and Gynecology and Sub-Board Diploma of Gynecologic Oncology in 1995. In addition, she was a Visiting Fellow in Gynecologic Oncology at Johns Hopkins Hospital in Maryland, Memorial-Sloan-Kettering Cancer Center in New York and M.D.Anderson Cancer Center in Texas, U.S.A. She is a member of many professional societies both domestic and international i.e. Medical Council of Thailand, Royal College of Obstetricians and Gynecologists of Thailand, International Gynecologic Cancer Society, Asian Gynecologic Oncology Group, Asian Society of Gynecologic Oncology and etc. and, at the same time, she is also a leading author of numerous publications and books in the field of Gynecologic Oncology.

How to Get National Immunization Program for HPV Vaccination: Sharing Experience — The Japanese Expert Board for the Eradication of Cervical Cancer

Konno R¹, Konishi I², Udagawa Y³, Suzuki M⁴, Yoshikawa H⁵, Kamura T⁶, Noda K⁷

Department of Obstetrics and Gynecology, Jichi Medical University Saitama Medical Center, Saitama, Japan¹, Kyoto University Graduate School of Medicine, Kyoto², Fujita Health University School of Medicine, Aichi³, Jichi Medical University, Tochigi⁴, University of Tsukuba, Tsukuba⁵, University of Kurume⁶, Kinki University, Osaka⁷

HPV vaccination is one of the most useful strategies to reduce cervical cancer. In Japan, routine vaccination is free, individual (clinic-based) and funded by regional governments. On the other hand, non-routine vaccines are basically self-pay. Clinical research on HPV vaccines targeted at Japanese women started in 2007. In November, 2008, we established the Japanese Expert Board for the Eradication of Cervical Cancer with goal of obtaining national funding for HPV vaccination as a routine vaccine and high coverage of more accurate screening. Members of the Project include Drs, Nurses, Midwives, Cancer survivors, and Cancer Association. We presented the recommendation with evidence showing the advantages and cost effectiveness for governmental funding. To educate and raise awareness in politicians, policy makers, health professionals, mass media and the general public, many educational campaigns, seminars and promotions were also implemented. Cervarix was licensed and became available first as a private (non-routine) vaccine from December, 2009. Since regional governments funding HPV vaccination with their own budget gradually increased, the national government judged the establishment of a specific fund for HPV vaccine targeted at girls aged 13 to 16 to be necessary. Consequently, the national government and regional governments provide a tentative budget half and half and an interim nationwide HPV vaccination program was started since November, 2010. Uptake ratio was estimated by MHLW at 70% (1st dose, March, 2012) of the target age groups. In May, 2012, Ministry of Health, Labour and Welfare approved HPV vaccination as part of the national routine immunisation program.

Curriculum Vitae

1984 M.D, Jichi Medical University, Japan
1991 Ph.D, Tohoku University School of Medicine, Japan (Thesis: HPV and cervical cancer)
2012 President, Japanese Association for Gynecological Cancer Screening Congress.

Invited speaker:

ACOS 2012, AOGIN 2012, IFCPC 2011, AOGIN 2011, AOGIN 2010, APCC 2009, etc.

Neoadjuvant Chemotherapy followed by Radical Hysterectomy plus Postoperative Chemotherapy but No Radiotherapy for Stage IB2-IIB Cervical Cancer

Takeshima N, Matoda M, Yamamoto A, Abe A, Machida H, Nomura H, Omatsu K, Kato K, Umayahara K

Department of Gynecology, Cancer Institute Hospital, Tokyo, Japan

Objective: To evaluate the effectiveness of neoadjuvant chemotherapy (NAC) followed by radical hysterectomy plus postoperative chemotherapy but no radiotherapy for stage IB2-IIB cervical cancer.

Methods: Forty-six consecutive patients with stage IB2-IIB cervical cancer were treated with NAC followed by radical hysterectomy plus postoperative chemotherapy. Median (range) body mass index (BMI) of the patients was 20.2 (16.2-26.4). Regimens for NAC and postoperative chemotherapy were irinotecan and cisplatin (CPT-11/CDDP) or CPT-11 and nedaplatin (CPT-11/NDP). A total of 6 cycles of NAC and postoperative chemotherapy were prescribed. No use of radiotherapy was scheduled, except in the case of a recurrence.

Results: With a median follow-up period for survivors of 38.8 months (range 24-54 months), the 2- and 3-year progression-free survival rates were 91.2% and 86.1%, respectively. Overall response rate of NAC was 80.4%. Recurrence was observed in 7 patients. In the absence of radiotherapy, pelvic recurrence was observed in only 3 patients; another 2 had para-aortic lymph nodes and the remaining 2 distant metastases. Toxicities due to chemotherapy were generally tolerable. Postoperative complications included urinary fistula (4 patients, 8.7%) and bowel obstruction (2 patients, 4.3%), all of which required surgical intervention.

Conclusion: The results indicate that NAC followed by surgery plus postoperative chemotherapy but no radiotherapy offers a viable option in the treatment of stage IB2-IIB cervical cancer. Although a relatively large incidence of postsurgical complications was observed among low-BMI patients, this treatment offers the advantage of minimizing radiation-induced morbidity, allowing radiotherapy to be reserved for the possible event of pelvic recurrence.

Curriculum Vitae

1983, March	Graduated from Yamaguchi University, School of Medicine
1988, October	Department of Obstetrics and Gynecology, Yamaguchi University, School of Medicine
1989-1990	Department of Pathology, Newcastle University (UK)
1992, February	Department of Gynecology, Cancer Institute Hospital (Tokyo)
2006, November	Vice-Director of Department of Gynecology, Cancer Institute Hospital (Tokyo)
2012, May~	Department Director of Gynecology, Cancer Institute Hospital (Tokyo)

Radical Hysterectomy for Locally Advanced Cervical Cancer: Essential Techniques

Masaki Mandai, Tsukasa Baba, Noriomi Matsumura, Koji Yamanoi, Kenzo Kosaka,
Yumiko Yoshioka, Junzo Hamanishi, Ikuo Konishi

Department of Gynecology and Obstetrics, Kyoto University Graduate School of Medicine, Kyoto,
Japan

Recently, the role of neoadjuvant chemotherapy for locally advanced cervical cancer is being re-assessed. Especially in case of IIb stage cervical cancer, the efficacy of NAC is likely to some extent to depend on the completeness in surgical tumor removal. In our analysis of 12 cases of stage Ib cervical cancer who underwent NAC, the number of LNs positive for metastasis (1/12) is smaller than the cases who underwent primary radical hysterectomy (6/17), suggesting that NAC provides some efficacy in controlling pelvic LN metastasis in these cases. By contrast, in stage IIb cases, the rate of LN metastasis (32/43) is still high even after NAC, similar to primary operation group (4/10). These data suggest that there is high risk of recurrence after NAC for stage IIb case, unless complete surgical removal of pelvic LNs was achieved.

In radical hysterectomy, sometimes gross tumor remains even after NAC, which makes complete removal of pelvic LNs difficult. In such case, the application of more extensive surgery, which is called as extended radical hysterectomy or total extirpation of internal iliac blood vessel system may be useful. In this procedure, first by cutting the internal iliac artery and vein, whole branches of internal iliac vessels are ultimately exposed and removed, which enables complete removal of LN tissue from the pelvic cavity.

Second important issue in the radical hysterectomy after NAC is the preservation of urinary function. Except for small number of cases in which remaining tumor was grossly extended into the parametrium, nerve-sparing radical hysterectomy could be performed safely in most of the stage IIb cases. However, the recurrent rate after NAC and radical hysterectomy was not sufficiently low (15/34), and further personalization of surgical procedure as well as choice of adjuvant therapy are thought to be important.

Curriculum Vitae

Associate Professor, Department of Gynecology and Obstetrics,
Kyoto University Graduate School of Medicine

Education; Faculty of Medicine, Kyoto University (1982.4-1988.3)

Working Experience;

1988.5-1989.1	Dept. of Gynecol/Obstet, Kyoto University Hospital
1989.2-1992.3	Hyogo Prefectural Amagasaki Hospital
1992.4-2000.10	Dept. of Gynecol/Obstet, Graduate School of Medicine, Kyoto University
2000.11-2002.11	Research Fellow, Vaccine Research Center, NIH, USA
2002. 12-	Dept. of Gynecol/Obstet, Graduate School of Medicine, Kyoto University

Research Field; gynecologic oncology

Peritoneal cytology: A significant prognostic factor of non-endometrioid endometrial cancer

Kyung Hee Han, Hee Seung Kim, Hyun Hoon Chung, Jae Weon Kim, Noh Hyun Park, Yong Sang Song
Department of Obstetrics and Gynecology, Seoul National University College of Medicine, Seoul, Korea

Purpose of the study: We investigated the differences of recurrence patterns between endometrioid endometrial adenocarcinoma (EM) and non-endometrioid endometrial adenocarcinoma (NEM). This study was conducted to determine the prognostic variables of NEM.

Method(s): Medical records of 490 patients diagnosed as endometrial adenocarcinoma between 2000 and 2012 were reviewed retrospectively. Baseline tumor characteristics, patient demographics and patterns of recurrence were compared between EM and NEM in order to determine the risk factors of tumor recurrence. Data was analyzed using χ^2 test and Fisher's exact test, and using Mann-Whitney U test in small cases. Univariate and multivariate regression analyses were also performed to identify the independent prognostic factors of NEM. Kaplan-Meier survival model was used to assess the prognostic effect on overall survival (OS) and Recurrence-free survival (RFS).

Result(s): Four hundred and forty eight patients were in EM and 42 were in NEM. Median follow-up time for this study was 71 months (range 12-150 months), and recurrence rates were higher in NEM (10/42, 23.8%) compared to EM (18/448, 4.0%). Clinicopathologic variables associated with tumor recurrence were age at diagnosis, FIGO stage, histologic grade, depth of myometrial invasion, adnexa involvement, and cervix extension in EM ($p=0.003$, <0.001 , 0.002 , 0.004 , <0.001 , 0.002 , respectively). On the other hand, FIGO stage and positive peritoneal cytology were possible predictor of recurrence in NEM ($p=0.024$, 0.003 , respectively). Positive peritoneal cytology was an independent prognostic factor of NEM by multivariate analysis ($p=0.006$). Median RFS of patients with positive peritoneal cytology was 14 months in NEM ($p<0.001$).

Conclusion(s): Positive peritoneal cytology is a valuable predictor for tumor recurrence and affects RFS in NEM.

L1CAM expression is associated with pelvic lymph node metastasis and advanced stage in diabetic patients with endometrial cancer: a matched case control study

Dong Hoon Suh¹, Min A Kim², Hee Seung Kim¹, Hyun Hoon Chung¹, Jae Weon Kim¹, Noh Hyun Park¹, Yong Sang Song¹,
Soon-Beom Kang³

Department of Obstetrics and Gynecology, Seoul National University College of Medicine, Seoul, Korea¹, Department of Pathology, Seoul National University College of Medicine, Seoul, Korea², Department of Obstetrics and Gynecology, Konkuk University School of Medicine, Seoul, Korea³

Purpose of the study: To investigate the association between L1 cell adhesion molecule (L1CAM) expression and lymph node (LN) metastasis in diabetic patients with endometrial cancer (EC).

Method(s): A matched case control study with each 34 diabetic and non-diabetic EC patients. L1CAM expression was evaluated by immunohistochemistry.

Result(s): Of the 68 patients, 6 (8.8%) were positive for L1CAM immunostaining. Positive rate of L1CAM expression in diabetic EC patients was similar to that in non-diabetic EC patients (14.7% vs. 23.5%, $p=.355$). Tumor recurred more in patients with positive L1CAM expression than those with negative L1CAM expression (33.3% vs. 1.6%, $p=.019$). However, we failed to find any significant association between L1CAM expression and LN metastasis. Only for the diabetic EC patients ($n=34$), patients with pelvic LN metastasis showed L1CAM expression more than those without LN metastasis (50.0% vs. 3.6%, $p=.035$). Advanced stage was the only risk factor for recurrence that showed a significant association with L1CAM expression for the diabetic EC patients ($p=.006$), as well as all the enrolled EC patients ($p=.014$).

Conclusion(s): L1CAM expression is associated with pelvic LN metastasis and advanced stage in diabetic patients with EC.

Laparoscopic versus open radical hysterectomy in patients with stage IB2 and IIA2 cervical cancer

Jeong-Yeol Park¹, Sang-Yoon Park², Dae-Yeon Kim¹, Jong-Hyeok Kim¹, Yong-Man Kim¹, Young-Tak Kim¹, Joo-Hyun Nam¹

Department of Obstetrics and Gynecology, University of Ulsan College of Medicine, Asan Medical Center, Seoul, Korea¹, Center for Uterine Cancer, Research Institute and Hospital, National Cancer Center, Gyeonggi-do, Republic of Korea²

Purpose of the study: To compare survival and surgical outcomes of laparoscopic (LRH) and open radical hysterectomy (ORH) in patients with stage IB2 and IIA2 cervical cancer.

Method(s): A retrospective analysis was performed on 303 patients with stage IB2 and IIA2 cervical cancer who underwent LRH (n=115) or ORH (n=188).

Result(s): Two patients (1.7%) in the LRH group required conversion to laparotomy. There was no difference with respect to operating time, perioperative change in hemoglobin level, and need for transfusion. However, in the LRH group, estimated blood loss (P=0.003) was significantly lower, time to recovery of bowel movement (P<0.001) and length of postoperative hospital stay (P<0.001) were significantly shorter, and postoperative complications were significantly less frequent (P=0.036). The 5-year disease-free survival was 78% in the LRH group and 77% in the ORH group (P=0.718), and 5-year overall survival was 83% in both groups (P=0.746). There were no differences in pattern of recurrence (P=0.225) and median time to recurrence (12 vs. 13 months; P=0.240).

Conclusion(s): LRH has similar therapeutic efficacy to ORH in patients with bulky early-stage cervical cancer. However, LRH has more favorable surgical outcomes. Therefore, LRH is not only a reasonable alternative to ORH but also the preferred surgical procedure for these patients.

Prognostic significance of nutritional risk index in advanced epithelial ovarian cancer

Jiheum Paek, Tae Wook Kong, Suk-Joon Chang, Ki-Hong Chang, Hee-Sug Ryu

Department of Obstetrics and Gynecology, Ajou University School of Medicine, Suwon, Republic of Korea

Purpose of the study: The purpose of this study was to evaluate the feasibility of principal recommended nutritional risk index (NRI) as a prognostic factor in patients with advanced epithelial ovarian cancer.

Method(s): A total of 150 advanced epithelial ovarian cancer patients were treated with debulking surgery, followed by taxane and platinum-based chemotherapy in the single institution. The NRI was derived from the serum albumin concentration and the ratio of actual to usual weight and was analyzed before surgery, and on the start and the end of chemotherapy (NRI1, NRI2, and NRI3, respectively).

Result(s): The NRI was not related to the number of chemotherapy cycles. The median duration of the follow-up was 37 months. The median progression-free survival of patients with low and very-low NRI3 were 17 and 7 months, respectively, whereas that of patients with normal NRI3 were 23 months (95% CI, 18-28 months) (p=0.008). The median overall survival (OS) of patients with very-low NRI3 was shortest among groups (13 months, 95% CI, 8-18 months, p<0.001). Independent predictor for OS included NRI2 and NRI3 (hazard ratio 1.19 and 1.65; p=0.018 and p<0.001, respectively).

Conclusion(s): The NRI before and after chemotherapy was a significant prognostic factor in patients with epithelial ovarian cancer who were treated with debulking surgery and adjuvant taxane and platinum-based chemotherapy.

● KSGO Session

The Clinical Significance of Human Lysyl-tRNA Synthetase (KRS) in Patients with Epithelial Ovarian Cancer

Yoo-Young Lee, Young Jae Cho, Jung-Joo Choi, Chel Hun Choi, Tae-Joong Kim, Jeong-Won Lee, Byoung-Gie Kim, Duk-Soo Bae
Department of Obstetrics and Gynecology Samsung Medical Center, Sungkyunkwan University School of Medicine, Seoul, Korea

Purpose of the study: Lysyl-tRNA synthetase (KRS) is one of the subtypes in Aminoacyl-tRNA synthetases, which is known for a key molecule for immune response. Recently it is suggested that KRS may be associated with cancer metastasis in vitro study. We investigated clinical significance of KRS overexpression in patients with epithelial ovarian carcinoma (EOC) and its functional role on cell migration and proliferation in ovarian carcinoma cell lines.

Method(s): KRS expression was evaluated by immunohistochemical analysis in 39 patients with EOC. In vitro experiment was performed with inhibition of KRS by KRS specific siRNA.

Result(s): High KRS expression in primary tumor correlated with higher incidence of advanced stage ($P=0.037$). KRS was highly expressed in A2780cp-20 and SKOV3ip-1 human ovarian cancer cell lines and inhibition of KRS by its specific siRNA significantly reduced cell migration and induced low expression of matrix metalloproteinase-9. However, KRS specific siRNA did not show anti-proliferative effect on cancer cells and prognosis on survival was not different based on the expression level of KRS in patients with EOC.

Conclusion(s): The results of our study suggest that KRS may be responsible for tumor invasion and metastasis in patients with EOC.

Genetic profiling to predict recurrence of early cervical cancer

Yoo-Young Lee, Young Jae Cho, Jung-Joo Choi, Chel Hun Choi, Tae-Joong Kim, Jeong-Won Lee, Duk-Soo Bae, Byoung-Gie Kim
Department of Obstetrics and Gynecology Samsung Medical Center, Sungkyunkwan University School of Medicine, Seoul, Korea

Purpose of the study: We compared the prediction powers for disease recurrence between gene set prognostic model and clinical prognostic model developed in a single large population to see whether genetic quantitative approach will have significant prognostic role in early cervical cancer patients who underwent radical hysterectomy with or without adjuvant therapies.

Method(s): Gene set model to predict disease free survival of early cervical cancer was developed using DASL assay dataset from the cohort of early cervical cancer patients who were treated with radical surgery with or without adjuvant therapies at the Samsung Medical Center of Sungkyunkwan University School of Medicine in Seoul, Korea, between January 2002 and September 2008. Clinical prediction model was also developed in the same cohort and the ability of predicting recurrence from each model was compared.

Result(s): Adequate DASL assay profiles were obtained in 300 patients and we selected 12 genes for the gene set model. When the proportions of patients were categorized as having a low or high risk by the prognostic scoring using these genes, the Kaplan-Meier curve showed significant different recurrence rate between two groups. Clinical model was developed using FIGO stage as well as post-surgical pathological findings. In multivariate Cox regression analysis of prognostic models, gene set prognostic model showed higher hazard ratio for recurrence of 9.95 with 95% CI of 5.48-18.1 when compared with the clinical prognostic model, which showed the hazard ratio of 1.96 with 95% CI of 1.29-2.97.

Conclusion(s): We could find that genetic quantitative approach may have better performance of predicting recurrence in early cervical cancer patients.

Metabolic Tumor Volume Measured by Preoperative 18F-FDG-PET/CT Predicts for Recurrence in Endometrial Cancer

Seung-Hyuk Shim¹, Dae-Yeon Kim¹, Dong-Yun Lee², Shin-Wha Lee¹, Jeong-Yeol Park¹, Jong-Jin Lee², Jong-Hyeok Kim¹, Yong-Man Kim¹, Young-Tak Kim¹, Joo-Hyun Nam¹

Department of Obstetrics and Gynecology, University of Ulsan College of Medicine, Asan Medical Center, Seoul, Korea¹, Department of Nuclear Medicine, University of Ulsan College of Medicine, Asan Medical Center, Seoul, Korea²

Purpose of the study: Metabolic tumor volume (MTV) and total lesion glycolysis (TLG) are functional tumor parameters which determine the metabolic activity of tumors with increased 18 fluorodeoxyglucose (18F-FDG) uptake on positron emission tomography/computed tomography (PET/CT). The goal of this study was to evaluate whether these parameters have prognostic value in patients with endometrial cancer.

Method(s): Between 2004 and 2009, 84 patients with endometrial cancer underwent preoperative 18F-FDG PET/CT at our institution. Patients' clinicopathologic data were reviewed from medical records retrospectively. We measured the SUV_{max} , SUV_{avg} , MTV, and TLG of the primary tumor. Cox proportional hazards analysis were used to identify the predictors for recurrence.

Result(s): The median progression free survival (PFS) duration was 48 (1-85) months. There were 12 cases of recurrence. In univariate analysis, factors predicting for recurrence were myometrial invasion ($P=0.012$), lymphovascular space invasion ($P=0.029$), lymph node metastasis ($P<0.001$), non-endometrioid histology ($p=0.002$), advanced FIGO stage ($p<0.001$), MTV ($p=0.001$), and TLG ($p=0.052$). However, multivariate analysis showed that only lymph node metastasis ($P=0.001$, hazard ratio [HR] 9.286, 95% confidence interval [CI] 2.614-32.986) and MTV ($P=0.009$, HR 1.007, 95% CI 1.002-1.013) remained as independent risk factors for recurrence. The Kaplan-Meier survival graph showed that patients with a high MTV (≥ 17.15) had a significantly lower PFS rate than those with a low MTV (<17.15 ; $p=0.034$, log-rank test).

Conclusion(s): MTV measured by preoperative 18F-FDG PET/CT was a significant independent prognostic factor predicting for recurrence in patients with endometrial cancer. This functional tumor parameter may be considered to plan further treatment and follow-up after operation.

Comparison of serum HE4 with CA125 for diagnosis of epithelial ovarian cancer

Yun Hwan Kim, Shin Hye Chung, Woong Ju, Seung Cheol Kim

Department of Obstetrics and Gynecology and Medical Research Institute, College of Medicine, Ewha Womans University, Seoul, South Korea

Purpose of the study: We aimed to compare the diagnostic value of serum HE4 with CA125 in patients with ovarian tumor.

Method(s): Total 94 serum samples were included, of which 32 were from epithelial ovarian cancer and 62 from benign ovarian tumor. Serum HE4 level was measured by using enzyme immunoassay, and the level of serum CA125 was determined by electrochemiluminescence immunoassay.

Result(s): Both serum CA125 and HE4 levels were significantly higher in patients with ovarian cancer than those with benign ovarian tumor (median CA125: 394.1 vs. 22.7 U/ml, median HE4: 56.7 vs. 18.5 pM, $p<0.01$). Among benign ovarian tumors, serum CA125 was significantly elevated in patients with endometriosis compare to those with non-endometriotic tumor (median CA125 32.0 vs 17.9 U/ml, $p=0.003$). However, serum HE4 level was not different between endometriotic and non-endometriotic ovarian tumors (median HE4 19.0 vs 18.2 pM, $p=0.41$). The receiver operating characteristics curve analysis showed that serum HE4 only had the most highest value of area under the curve compared with CA125, and the combination of two biomarkers to diagnose the ovarian cancer (0.93 vs. 0.85 vs. 0.89)).

Conclusion(s): Serum HE4 level alone can increase the accuracy of ovarian cancer detection, and provides most valuable information to differentiate ovarian cancer from other benign ovarian tumors.

Chairpersons

A

Aoki, Daisuke Topics 5

B

Bae, Duk-Soo Topics 5

D

Domingo, Efren Topics 4

I

Inaba, Noriyuki Topics 1

K

Kanzaki, Hideharu Topics 4

Katabuchi, Hidetaka Topics 3

Kigawa, Jyunzo Evening Seminar

Kim, Byoung-Gie Topics 3

Kim, Seung-Cheol Topics 1

Kimura, Tadashi Topics 2-1

Kitawaki, Jo Luncheon Seminar

Kobayashi, Hiroshi Topics 2-2

N

Ngan, Hextan YS Topics 2-1

O

Ochiai, Kazunori Luncheon Seminar

R

Ryu, Hee Sug Topics 3

S

Sugiyama, Toru Evening Seminar

W

Wang, Kung-Liahng Topics 2-2

